

**ST. VINCENT'S HEALTH
DEPARTMENT OF ANAESTHESIA
AND ACUTE PAIN MEDICINE**



**FIBREOPTIC INTUBATION
TRAINING MANUAL 2016**



This manual is dedicated to Vivian Nguyen who helped immensely in the preparation of the very first edition. She gave so much to so many, may she live on in our hearts and minds.

Foreword

Welcome to the 2016 edition of the Fiberoptic Intubation Training Manual.

The essential components of successful endoscopy are familiarity with equipment, anatomy recognition, patient management and dexterity. This manual can help with the first three aspects but the last, dexterity, is best initially developed in benchtop training.

These notes are a collection of facts, thoughts and experiences collated from multiple books, manuals, websites, courses and people in this department. The majority of the equipment in this manual is specific to St. Vincent's Hospital. The notes are arranged into modules which are designed to be completed in order.

Please feel free to provide feedback to improve future editions.

Crispin Wan
Editor

Many thanks to all the others who have made a contribution to this manual. In no particular order they are: Simon Scharf, Amanda Honour, Roberta Deam, Des McGlade, Russell Cook, Daniel Wong, Alison Graham.

Table of Contents

Foreword

Module 1: The Bronchoscope

Module 2: Ancillary Equipment

Module 3: Patient & Anatomy

Module 4: Topicalisation & Sedation

Module 5: Bronchoscopic Technique

Module 6: Benchtop Training

Module 7: Intubating through a LMA

Module 8: Thoracics


Further Reading

Quick Reference

Module 1: The Bronchoscope

How does it work

There are 3 main parts to all bronchoscopes: handle, insertion cord and flexible tip.



Olympus BF type PE2

Handle

The handle contains the control lever, working channel port, suction connector and button.

Control lever

- Controls the flexible tip.
- Two wires extend from the handle to the tip in the insertion cord.
- Only permits movement in one plane – up and down
 - Moving the lever down points the tip up
 - Moving the lever up points the tip down
- Side to side movement is accomplished by rotation of the handle of the bronchoscope with the operator's wrist.

Working channel port

- For instillation of oxygen or local anaesthetic delivery.

Suction connector

- For connecting up to suction

Suction button

- To activate suction

Insertion cord and flexible tip


There are usually four specific components which travel in the insertion cord

1. Working channel which can be used for suction, oxygen or injection of local anaesthetic.
2. Angulation wires initiating movement in opposite directions.
3. Light bundles for the transmission of light.
4. Image bundle for transmission of identical patient images from the distal lens to the proximal one.

There are 2 types of bronchoscopes: fiberoptic and video.

The main differences are in how images are obtained and transmitted, as well as the light source.

Fibreoptic Bronchoscopes (Fibrescopes)



Olympus LF-GP

Components

1. Eye piece: For optical viewing or can be attached to a camera for display on a screen.
2. Diopter ring: Used for focusing the image
3. Control lever: Used to point bronchoscope up or down
4. Working channel port, suction button and connector
5. Light source: Can be a portable battery powered source or via a cable.
Cable light source may be halogen or LED.
6. Insertion cord: Contains fibreoptic bundle for light and image transmission, tip bending control wires and a working channel.

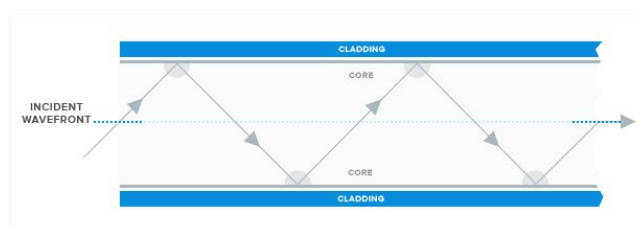
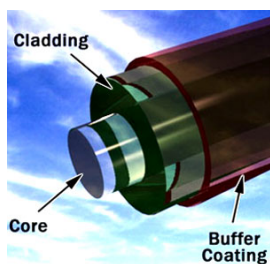
What are fibreoptics?

Fibreoptics are long, thin strands of pure glass about the diameter of a human hair. They are arranged in bundles and used to transmit light/images.

Core: Thin glass centre where the light travels

Cladding: Outer optical material surrounding the core to reflect the light back into the core

Buffer coating: Plastic coating that protects the fibre from damage and moisture



The light in a fibreoptic cable travels through the core by constantly bouncing from the cladding. The cladding doesn't absorb any light. The light signal does degrade as it travels along the fibre due to impurities in the glass.

Fibreoptic scopes at St. Vincent's

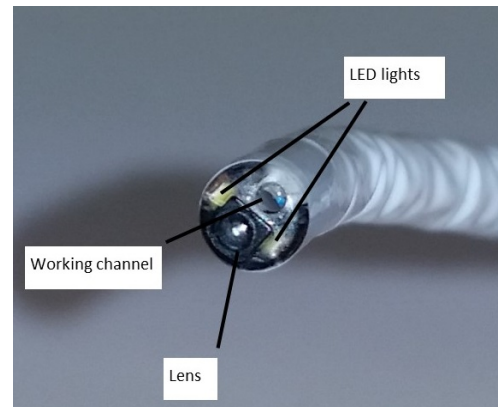
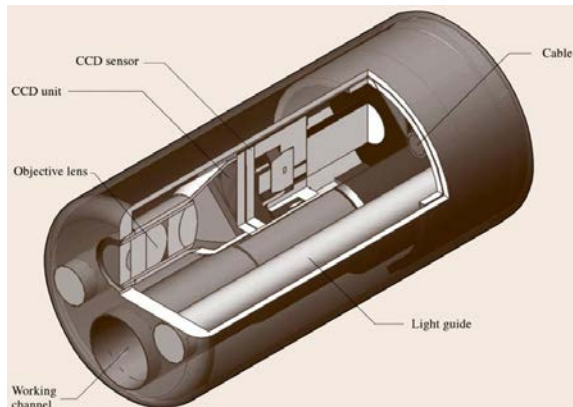
- Olympus LF-DP: 3.1 mm diameter insertion cord (very similar to LF-GP just narrower)
- Olympus LF-GP: 4.1 mm diameter insertion cord
- Olympus BF type PE2: 5.0 mm diameter insertion cord (shorter light cord)
marked "Optical Bronchoscope" in the Anaesthetic Workroom

Video Bronchoscopes (Videoscopes)


The image transmission in a videoscope differs from a fibrescope whereas the light transmission in a videoscope may or may not be fibreoptic based.

Images in a videoscope are focussed through a lens at the very tip of the scope onto a camera chip inside the distal end of the scope. The camera chip can be a CCD (charge coupled device) or CMOS (complimentary metal-oxide semiconductor).

The images are converted by the camera chip into digital signals which obviates the need for a fibreoptic component for image transmission. The digital signals are then transmitted to a digital processor which converts it back to an image that we see on the screen.



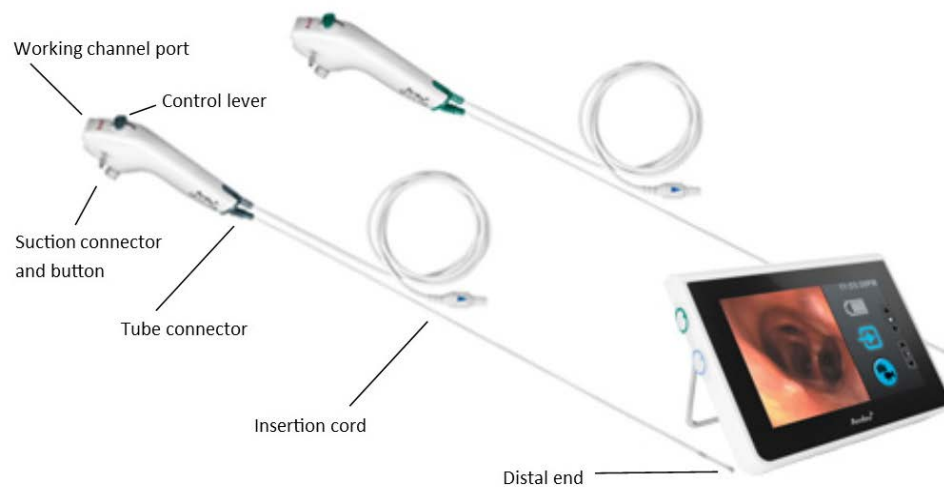
Olympus LF-V



Features:

- CCD camera sensor mounted at distal end of scope
- Fibreoptic light source
- Integrated light and image connector cable
- Connectors for suctioning/working channel port

Ambu aScope



Features:

- CMOS camera sensor at distal end of scope
- Twin LED lights at the distal end so there is no need for a light cable
- There is no “fiberoptic component” in this scope
- Available in 2 sizes (aScope 3 [green handle] and aScope 3 slim [grey handle])
- Tube connector for parking a tube when loaded (no need for tape) Introducer connector in packet can be used to facilitate use of luer lock syringes

Table

Scope	Type	Outer diameter	Min. size ETT	Min. size DLT	Working channel	Length	Tip mvmt	Field of view
Ambu	aScope 3	5.0 mm	6.0 mm	41 Fr	2.2 mm	600 mm	150° up 130° down	85°
	aScope 3 Slim	3.8 mm	5.0 mm	37 Fr	1.2 mm	600 mm	130°	85°
Olympus	LF-V	4.1 mm	5.0 mm	37 Fr	1.2 mm	600 mm	120°	120°
	LF-DP	3.1 mm	4.0 mm	32 Fr	1.2 mm	600 mm	120°	90°
	LF-GP	4.1 mm	5.0 mm	37 Fr	1.5 mm	600 mm	120°	90°
	BF type PE2	4.9 mm	6.0 mm	41 Fr	2.2 mm	600 mm	180° up 130° down	120°

Which one should I use?

For an Awake/Asleep Intubation or Intubating through an LMA:

Use the following non-disposable scopes: **Olympus LF-V, LF-GP or BF type PE2**

If a non-disposable scope is not available use an aScope 3 (less gap) if available otherwise use an aScope 3 Slim

The LF-DP is too slim (increased gap between scope and tube) and is easily damaged

For Thoracics:

Use this disposable scope: **Ambu aScope 3 Slim**

With good lubrication it should fit into a DLT 35 Fr or if using a bronchial blocker

If not available use an Olympus LF-V

An alternative for a DLT 35 Fr is an Olympus LF-DP

Please refer to Module 8 Thoracics for compatibilities with bronchial blockers

For Nasendoscopy:

Use an Olympus LF-DP (non-disposable) or an aScope 3 Slim (disposable)

Care of the Bronchoscope

- It is **VERY EASY TO DAMAGE** a non-disposable bronchoscope. The glass fibres inside the insertion tube are very fragile. Repairs are **VERY EXPENSIVE**.
- Protect** the scope if you're intubating orally with an Ovassapian or a Berman airway
- Do not** push against resistance.
- Always** relubricate the scope before inserting again.
- If the scope appears to be stuck try putting some saline down to try to rehydrate the lube.
- Leak tests are done before using the scope and after using the scope to determine if the scope was damaged intra-operatively.

How do I connect up the Bronchoscope

Ambu aScopes

The Ambu aScopes come with a dedicated screen attached to a pole. We have 2 of them in the Anaesthetic Workroom.



Connect up the connector from the aScope into the blue plug of the screen. Be gentle as the plug has been wrecked from too much force.



Video/Light Stack

The other scopes need a video/light stack of which we have 3 towers.

Olympus LF-V

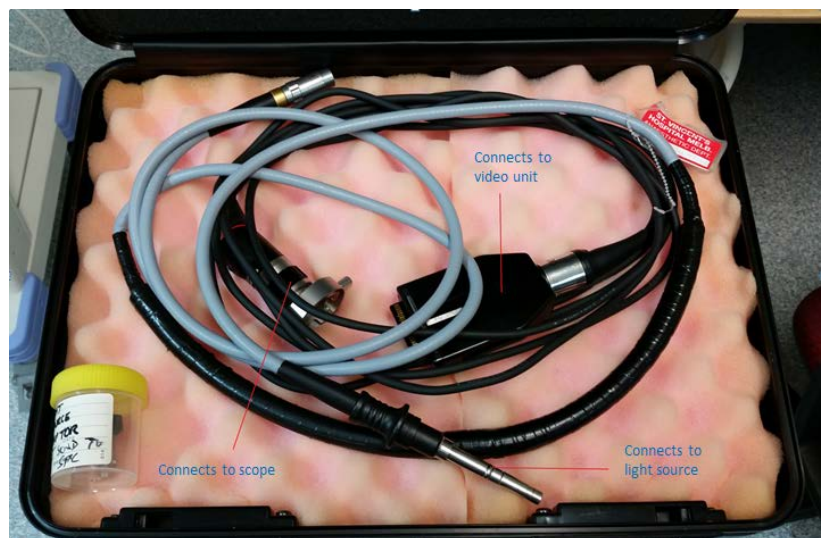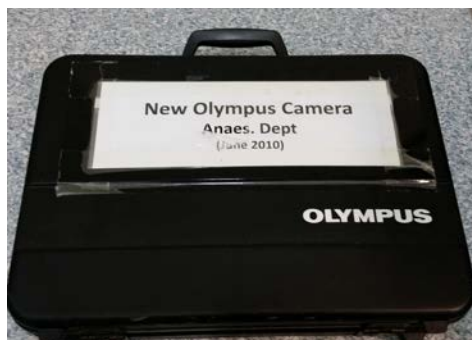- Has a single connector cable which splits into two (one light source connector and one video connector).

Olympus LF-DP, LF-GP and BF type PE2

- Has two light source options
 - Mobile battery-powered light source
 - Light cable which attaches to the light source. You'll need a small adaptor (in the box) to connect it to the scope.
- You can either look through the eyepiece or attach a camera to the eyepiece.
- If you attach a camera, you have to line up the camera to what you consider is up or down.



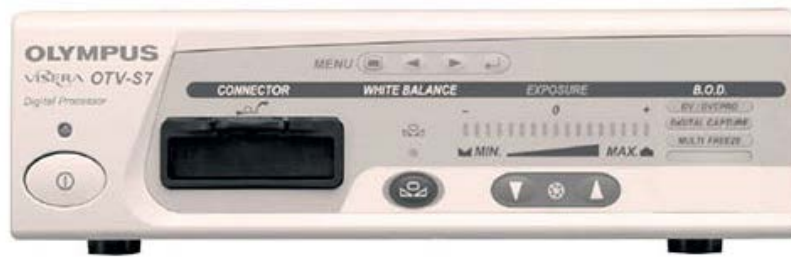Attachment cables/connectors for non-videoscopes



Grab the box with the cables/connectors which lives on one of the stacks.

Diagram above shows which bits connect to what.


Olympus OTV-S7 Video Unit



Digital processor unit for decoding digital signals for videoscopes (Olympus LF-V). Insert the video connector (refer to LF-V picture above) into here.

Used in conjunction with the Olympus CLV SL-40 (below) for accompanying light source unless you're using a portable battery light source with a non-videoscope.

Olympus CLV-S40 Light Source



Light source, connect light source connector into this unit.

Xenon light source.

Make sure it's not in standby mode (press power button in the middle if there's no light).



Connectors inserted into video and light source units

Olympus OTV-S5 (one stack only) Video Unit



Alternative older video attachment for non-videoscopes.

Comes with its own camera attachment and light source connector.

Used in conjunction with the CLK-4

Olympus CLK-4 (one stack only) Light Source



Alternative older light source used with the OTV-S5 which uses a halogen light source.

Module 2: Ancillary Equipment

Endotracheal tube

It is important to choose an appropriate size and type of tube to facilitate ease of intubation with a fiberoptic scope.


Sizing

Considerations:

- The tube needs to be:
 - Big enough to:
 - Allow adequate ventilation
 - Fit the scope
 - But small enough to:
 - Minimise the gap between the tube and the scope
 - Fit through the nose (if intubating nasally)
- The bigger the gap between the tube and the scope the more likely it is to snag on tissue eg. Epiglottis.
- Appropriate sized nasal tubes are 6-7 to reduce inadvertent turbinectomies and permit ease of passage.

Type

Normal ETT



Advantages: Acceptable to ICU

Disadvantages: Not flexible, unlikely to negotiate corners well, not suitable for nasal intubation

Reinforced ETT

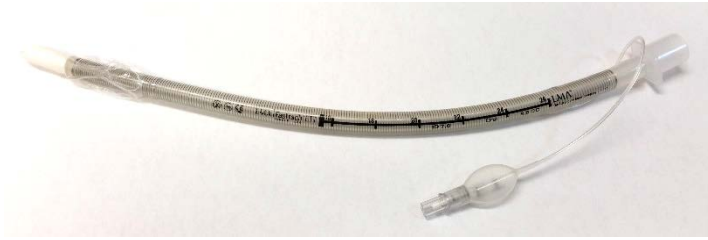


Advantages: Easier to negotiate corners

Disadvantages: Not recommended for long-term use eg. ICU

No Murphy eye (St. Vincent's stock)


Intubating LMA ETT



- Advantages:**
- Soft tip reduces risk of trauma
 - Snug tip reduces the gap between tube and scope
 - Flexible tube makes it easier to negotiate corners

Disadvantages: Length may be an issue

Parker flex ETT



This ETT has a flexible, curved, centred, tapered distal tip.

It is designed to flex and slide past protruding airway structures (vocal cords, turbinates).

The tip lies close to the introducer/scope to reduce the gap between the tube and the introducer/scope.

Advantages: Reduced incidence of difficulty passing tube over scope

Disadvantages: Not as good as ILMA tube for railroading

Nasal RAE



Increases in length with bigger diameter tubes

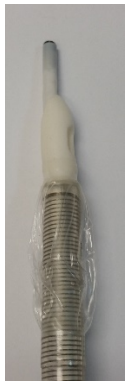Eg. #6.0 is 25 cm at nasal bend, #6.5 is 26 cm at nasal bend, #7.0 is 27 cm at nasal bend

There shouldn't be any reason to put anything bigger than #7.0 down a nose

Advantages: Long enough even if using small diameter tubes

Disadvantages: Pre-formed curve is not conducive to keeping the scope straight and it is harder to manipulate during railroading

Mind the Gap



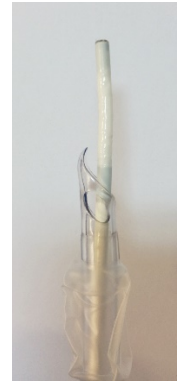
ILMA tube



Reinforced tube



Normal tube



Parker flex tube

The above pictures show the gap between the tube (all #7.5) and the scope.

The bigger the gap at the tip, the easier it is to snag on other structures. If there is difficulty advancing the tube, the tube is likely caught on the right arytenoid (does not apply to ILMA and Parker flex tube). In this scenario forcing the tube through may cause trauma. It is better to first withdraw the tube slightly and then rotate the tube 90° before readvancing. This will shift the bevel (posterior for counter clockwise, anterior for clockwise) to a more favourable position.

Conversely, the smaller the gap between the tube and the scope, the harder it is to slide off without adequate lubrication.

The big advantages of the ILMA tube are the soft tip and the reduced gap between the scope and the tube at the tip which allows the use of a relatively bigger sized tube.

Is it Long Enough (Nasal Intubation)?

The length of tube needed is dependent on the height of the patient.

This can be roughly calculated with the Chula formula

- Length of tube = $9 + (\text{height[cm]}/10)$.

Typical sizes

- Males 26 cm
- Females 24 cm

ILMA tube markings go to 26 cm but are about 29 cm long in total so should be adequate for all but the tallest patients.

Is it Small Enough (Nasal Intubation)?

A smaller size is used for nasal intubation compared to an oral intubation.

Typically

- Male: #6.5-7.0 (up to #8.0 is possible)
- Female: #6.0-6.5 (up to #7.0 is possible)

Choosing the size of the tube is a balance between being small enough to go through the nares (likely less trauma to nasal structures and epistaxis), long enough to sit in the trachea and having a

cuff that adequately seals the trachea. Many tend to choose a smaller tube as length and cuff seal don't appear to be an issue unless you have a very tall person. However some others do routinely use comparatively larger sizes without any issues.

It can be very frustrating being unable to railroad the tube despite successful navigation of the scope past the cords!

There are some who prefer to serially dilate the nostril with nasopharyngeal airways beforehand.

Note: A similarly sized ETT may not pass as nasopharyngeal airways are softer and more pliable.

Intubation Aids

These are used to assist with oral intubation. Lubricating the intubation aid with lignocaine gel can enhance topicalisation. Ensure that it stays in the midline.

Ovassapian



Used for protecting the scope and keeping the scope in the midline.

The Ovassapian airway is only available in a single size which may be problematic.

Can be opened wide to disengage it from the ETT.

Berman



Also used for protecting the scope and keeping the scope midline. The flange of the Berman can be tilted back and forth to improve the view. The airway can be prized open (lateral opening right side, hinge on left).

The Berman airway is available in multiple sizes but is not available currently at St. Vincent's.

Module 3: Patient

Who needs a fibreoptic intubation?

It is best suited to the non-emergent expected difficult airway - particularly the patient who is predicted to be difficult to intubate and ventilate.

- Difficult intubation
 - Known difficult intubation
 - Suspected difficult intubation
 - Rescue of failed intubation
- Difficult ventilation
 - Known/suspected difficult facemask ventilation
 - Known/suspected difficult LMA placement
- Cervical spine instability

Who shouldn't have a fibreoptic intubation?

- Absolute contraindications
 - Lack of endoscopic skill, assistance or equipment
 - Near total upper airway obstruction
 - Patient refusal (awake fibreoptic)
 - Uncooperative patients (awake fibreoptic)
- Relative contraindications
 - Inability to tolerate apnea
 - Blood or secretions in the airway

Patient preparation

Consent

- Explain the whole process to the patient
- Explain to the patient why they require an awake intubation and each step of the process
- Answer any questions the patient may have
- It is important to establish rapport as co-operation is an integral part of the process

Patient positioning

Option 1: Patient supine with operator in the normal intubating position

Option 2: Patient sitting upright and facing the operator

Oral vs nasal

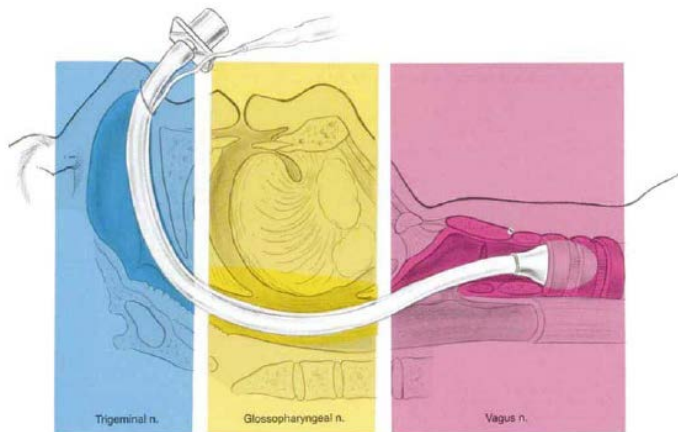
Oral	Nasal
Advantages Larger ETT possible Shorter route No turbinectomies/epistaxis Disadvantages Less direct pathway Easy to stray from midline Topicalisation must be optimal	Advantages Allows surgical access to mouth Possible if limited mouth opening Direct pathway to vocal cords Disadvantages ETT size limitation Damage to turbinates & epistaxis Not suitable if nasal pathology present

Which nostril?

Pick the more patent nostril. Test this by getting the patient to block one nostril and inhale.

Note: if the patient has a deviated septum, usually the bigger nostril aperture indicates the narrower nostril (this is because the deviated septum goes into the contralateral side before coming back)

Anatomy



Taken from: Atlas of Regional Anesthesia
2nd ed., 1999, David L. Brown

Nerves

Innervation of Nose and Nasopharynx

- Cranial nerve V (Trigeminal): Ophthalmic and maxillary divisions
 - Anterior ethmoid, infraorbital, anterior superior alveolar, olfactory, sphenopalatine

Innervation of Pharynx

- Cranial nerve IX (Glossopharyngeal)
 - Posterior 1/3 tongue, valleculae, lingual surface of epiglottis
 - Anterior 2/3 tongue by lingual n. (branch of trigeminal n.)

Innervation of Larynx (CN X)

- Cranial nerve X (Vagus)
 - Superior laryngeal nerve: epiglottis to above vocal cords
 - Recurrent laryngeal nerve: vocal cords and down to upper trachea

Reflexes

Gag reflex

- Afferent: Glossopharyngeal
- Efferent: Vagus

Cough reflex

- Afferent: Vagus

Glottic closure reflex (exaggeration = laryngospasm)

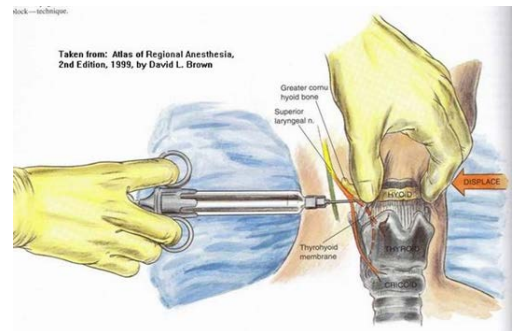
- Afferent: Superior Laryngeal Nerve
- Efferent: Superior & Recurrent Laryngeal Nerve

Nerve Blocks

Requires normal neck anatomy & non-infected site

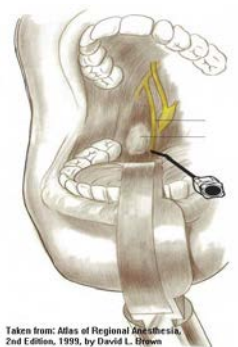
Superior Laryngeal

- Position
 - Supine with head maximally extended
- Identify greater cornu of hyoid
- Coming from lateral direction point needle caudally and walk off hyoid bone into thyrohyoid membrane
- When a give is felt, aspirate for air or blood
- Inject 2 ml of 2% lignocaine
- Repeat on other side
- **Warnings:**
 - Do not pierce thyroid cartilage as deposition of LA here can cause oedema of vocal cords
 - Do not “pinch” hyoid as you can easily fracture it
- Disadvantage: anatomy may be difficult to identify



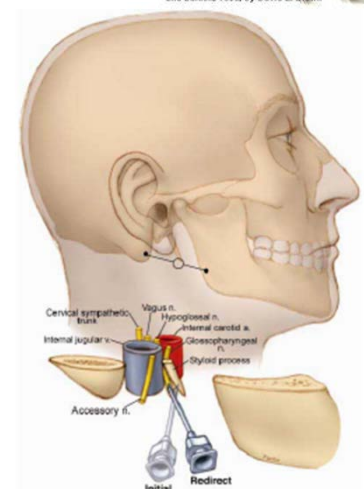
Glossopharyngeal: Intraoral approach

- Requires adequate mouth opening
- Retract tongue with tongue depressor to visualise of inferior tonsillar pillars
- Needle advanced into submucosal tissue at caudal aspect of posterior tonsillar pillar
- Inject 5ml of 2% lignocaine + 1:200,000 Adrenaline
- Safer alternative is to use cotton buds soaked with local anaesthetic instead of injecting and hold at the same site



Glossopharyngeal: Peristyloid approach

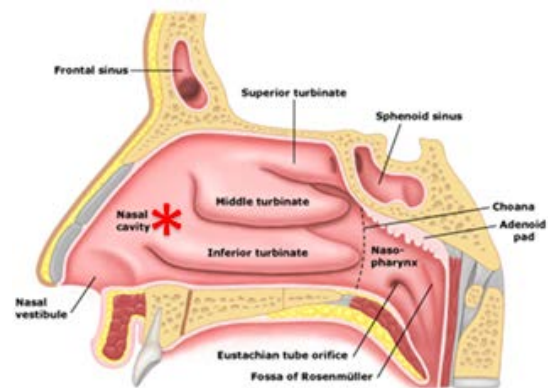
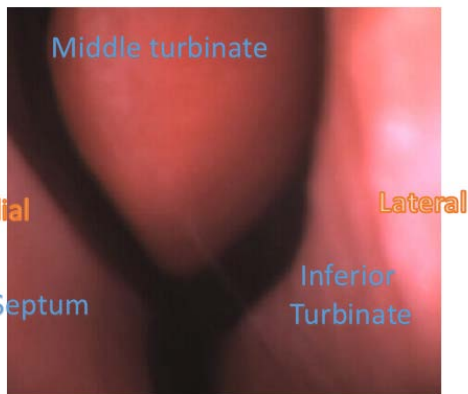
- Position:
 - Supine with head neutral
- Draw a line between angle of the jaw and mastoid process
- Deep palpation to find styloid process
- Insert needle at midpoint of line to contact styloid process
- Walk off styloid process in posterior direction
- Aspirate and inject 5-7ml of 2% lignocaine + 1:200,000 Adrenaline
- “Tiger territory”
 - Risk of injection into ICA and IJA



Anatomy: Endoscopic

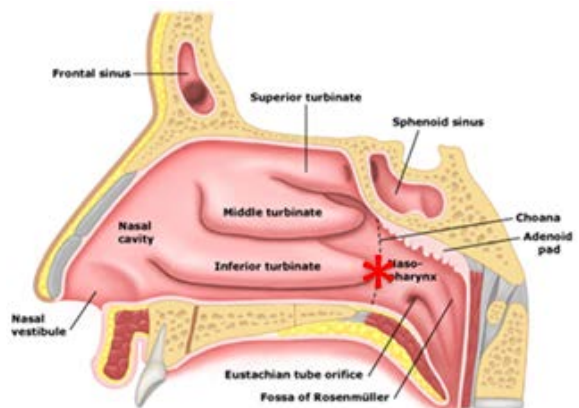
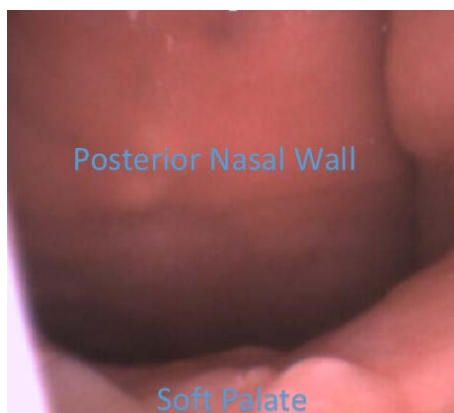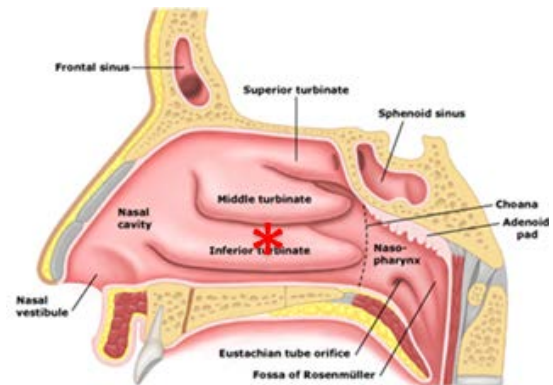
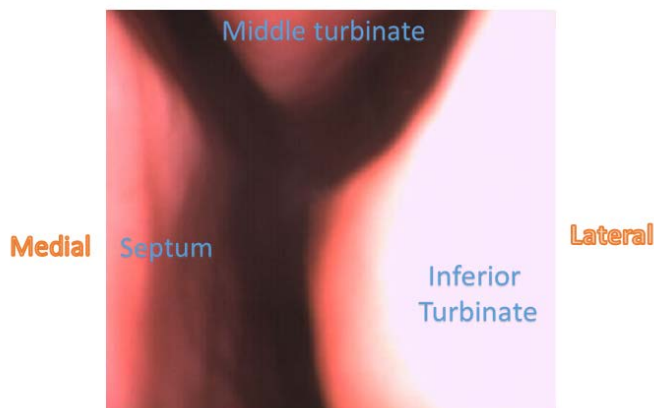
This section describes the structures you should recognise as you perform a bronchoscope

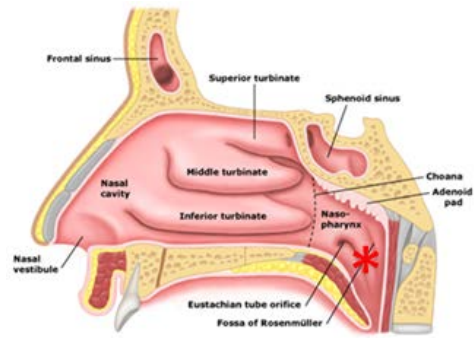
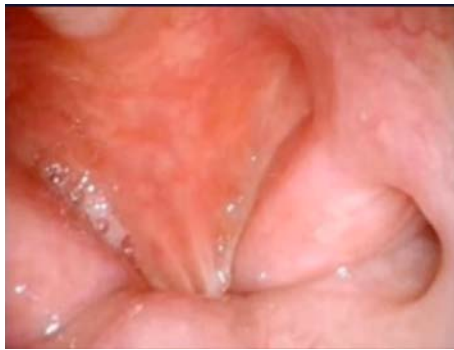Nasal Approach (Standing in front of patient)



As you enter the nose you should follow the path either under the inferior turbinate or between middle and inferior turbinate. This is a horizontal path. Try not to go above the middle turbinate.

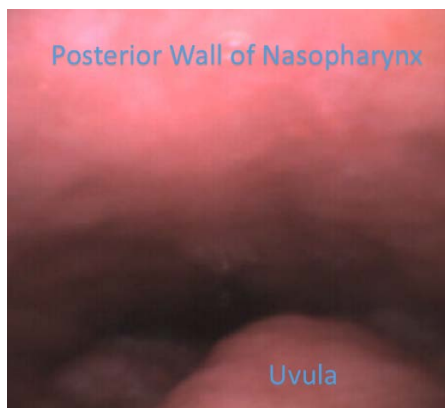
Note: these images correspond to what you will see facing the patient.



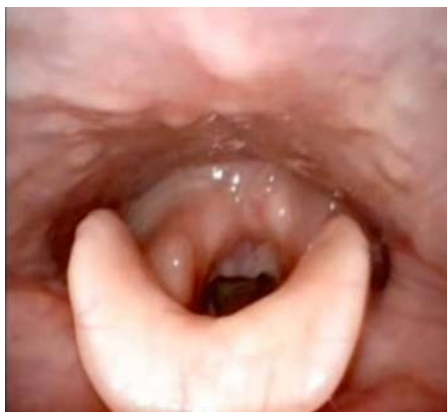

Depending on your topicalisation the patient can swallow at this point. This closes the nasopharynx. Get the patient to sniff in to get the palate to drop down out of the way, as soon as it drops go forward! Be ready, at this point you need to flex downwards.

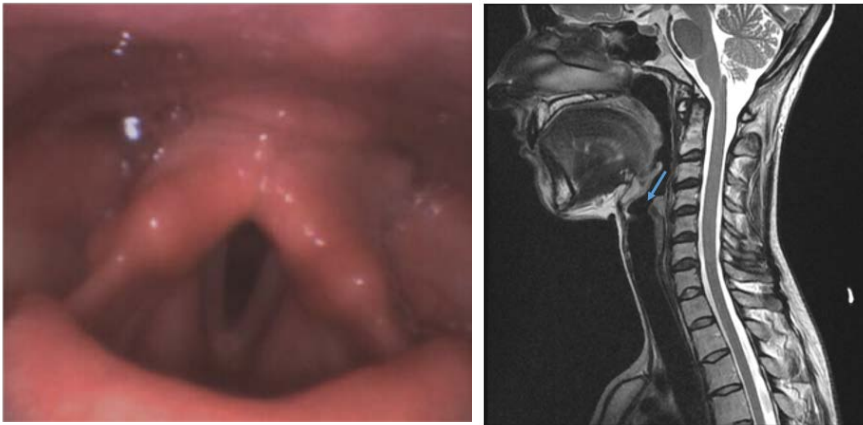As you enter the nasopharynx follow the soft palate down to the uvula.



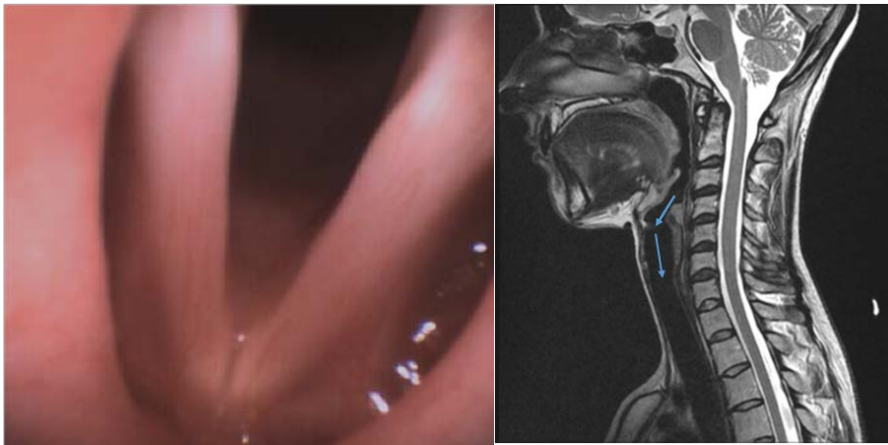At the uvula you'll enter the oropharynx. If the patient is asleep, use jaw thrust to lift the tongue and/or Magills forceps to pull the tongue out to reveal the larynx.



The larynx is now in view.

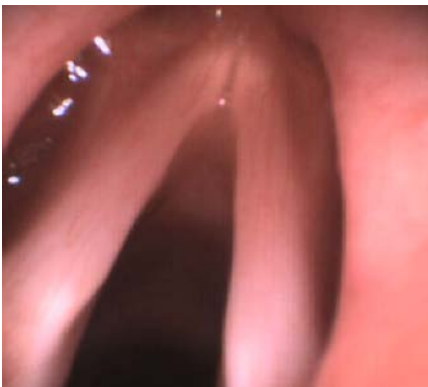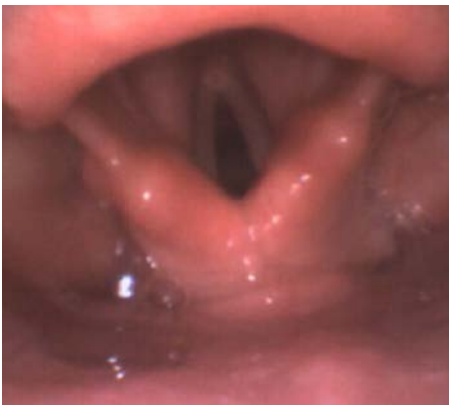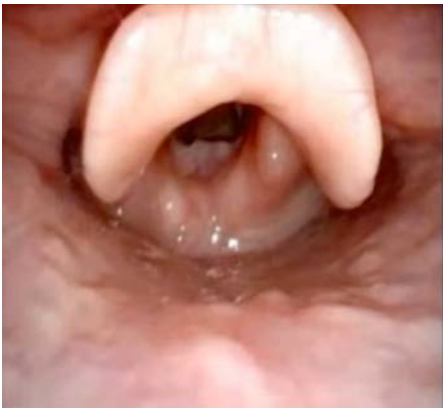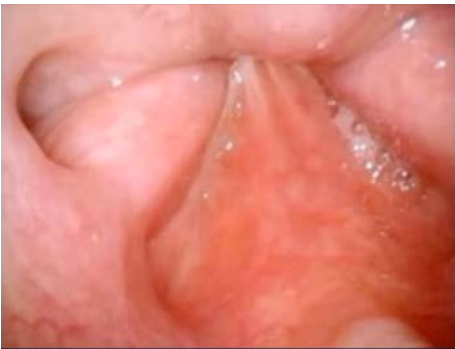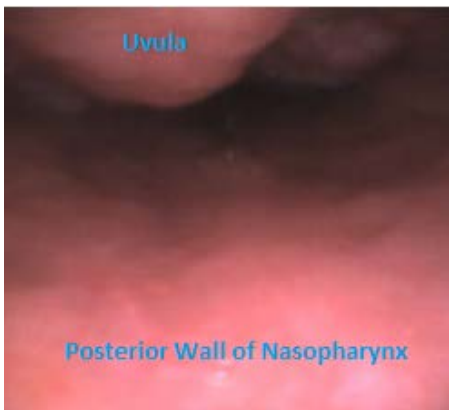
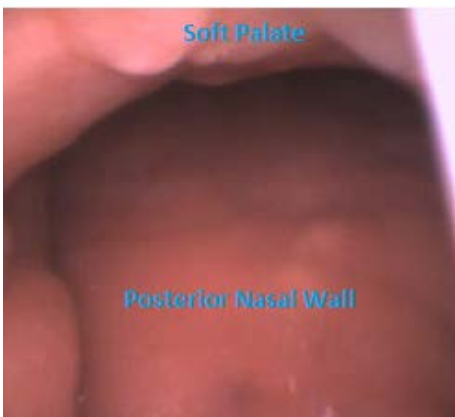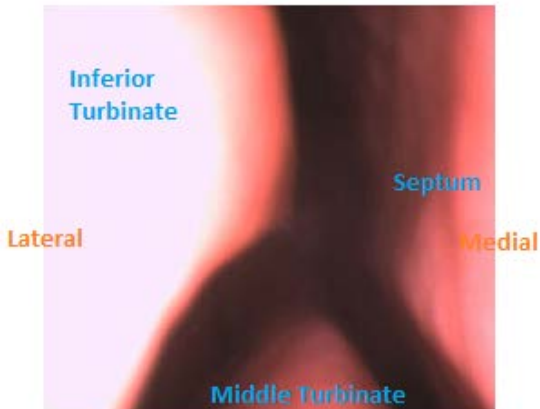
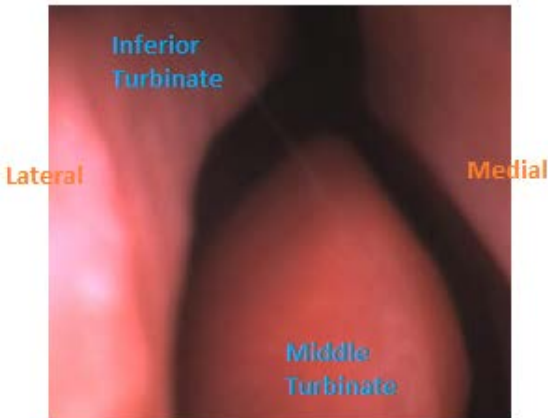


Note that the larynx is slightly anterior. Flexing the scope will help your approach to the vocal cords.

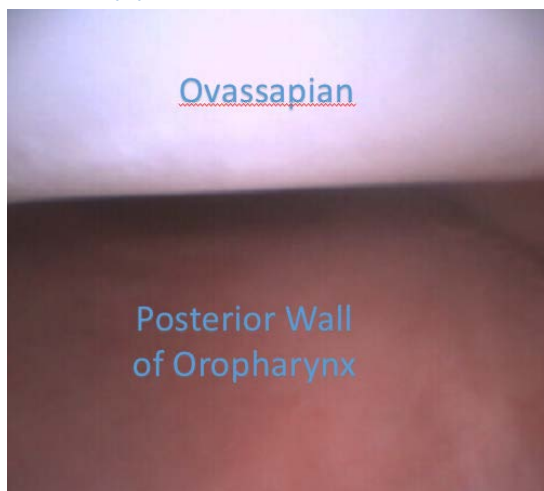

Once you're at the vocal cords you have to retroflex the scope to enter into the trachea and avoid hitting the anterior wall of the trachea.

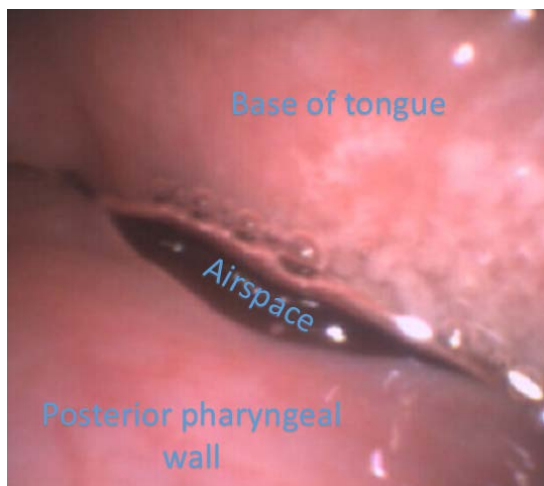
Nasal Approach (Standing behind patient's head)



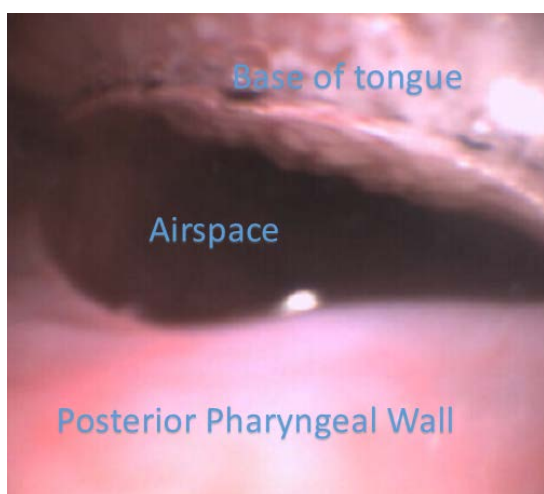
Oral Approach



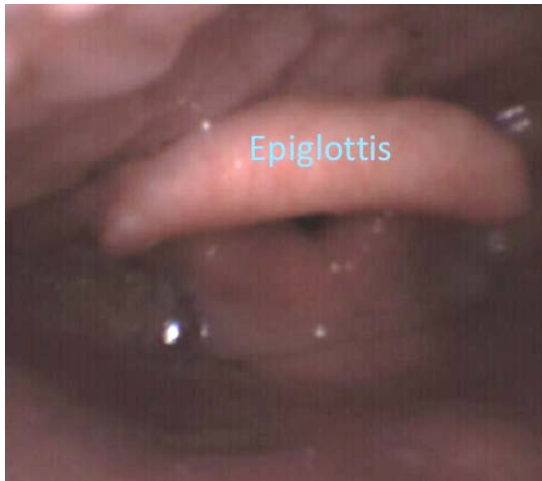Intubation with Ovassapian shown in picture above.



As you exit the Ovassapian you'll be at the base of tongue or larynx. There might be little airspace to get into. Some jaw lift or tongue pull (gauze or Magills) will open up the posterior oral pharynx.



Here some jaw thrust has opened up the airspace.



Advancing a little further brings the larynx into view.

Module 4: Topicalisation & Sedation

Sample approaches by various consultants in the department

Detailed below are how various consultants approach topicalisation/sedation for an awake intubation. There are many and varied approaches and are influenced by personal preference and what they've learnt/experienced in the past. They can all work quite well.

Pre-procedure glycopyrrolate is recommended.

Simon/Amanda

Nasal: Vasoconstrictor - co-phenylcaine
Serial dilation with nasopharyngeal airway (2% lignocaine)
Oral: 10% lignocaine spray to oropharynx or oral MAD device
Sedation: Midazolam (optional)
Analgesia: Remifentanyl (0.05-0.1 mcg/kg/min)

Bertie

Nasal: Vasoconstrictor - co-phenylcaine; 4% lignocaine spray with oral MAD through the nose 4 ml x2
Oral: 4% lignocaine spray with oral MAD oropharynx x2
Block: Transtracheal injection
Sedation: Midazolam (optional)
Analgesia: Fentanyl (optional)

Crispin

Nasal: Vasoconstrictor - co-phenylcaine or cocaine (Moffett's)
Atomiser: home-made atomiser
Oral: 4% lignocaine spray with oral MAD
Topup: 2 ml of 2-4% lignocaine spray as you go
Block: Transtracheal injection
Sedation: Propofol TCI (if appropriate)
Analgesia: Remifentanyl TCI (if appropriate)

Vivian

Nasal: Vasoconstrictor – co-phenylcaine
Oral: Xylocard nebuliser and lignocaine gargle
Block: Transtracheal injection
Sedation: Propofol TCI (if appropriate)
Analgesia: Remifentanyl TCI (if appropriate)

Topicalisation

With regards to topicalisation for any awake intubation there are 3 essential components:

1. Antisialagogue
2. Vasoconstrictor
3. Local anaesthetic

Antisialagogue

Drying up secretions will -

- Aid visualisation
- Improve local anaesthetic efficacy (decreases dilution by secretions and improve surface absorption)

Glycopyrrolate

- 0.2-0.4 mg IV/IM
- Needs a minimum of 15-30 mins to work
- Drawback: tachycardia may be undesirable

	Sedation	Antisialagogue	Increase Heart Rate
Atropine	+	+	+++
Scopolamine	+++	+++	+
Glycopyrrolate	0	++	++

NOTE. 0 = none, + = mild, ++ = moderate, +++ = marked.
Adapted and reprinted.¹⁷

Vasoconstrictors

Nasal mucosal vasoconstriction can improve visualisation, open up nasal passages, limit bleeding and limit local anaesthetic absorption

Drugs:

- Phenylephrine
- Cocaine
- Adrenaline
- Oxymetazoline

Local Anaesthetics

Local anaesthetics are used to improve tolerability of the procedure. With good topicalisation the procedure can be performed easily without sedation or undue patient distress.

Lignocaine

Available preparations:

1% solution, 2% solution, 2% jelly, 2% oral gel,
2% viscous, 4% topical, 5% ointment, 10% spray,
Co-phenylcaine

Maximum dose: 8 mg/kg for upper airway topicalisation (this limit does not apply to blocks)

Where possible keep to the lowest dose possible. Depending on the technique, using only 3 mg/kg is achievable.

There has been one case report of death with a topicalisation dose of 1200 mg lignocaine.

Metabolism: 70% removed via hepatic metabolism if swallowed

It does NOT taste nice!

Lignocaine 10% spray

1 spray = 10 mg

Is effective but has an unpleasant sensation (like chilli pepper) and tastes bitter

You will still need vasoconstriction if going through the nose



Co-phenylcaine spray

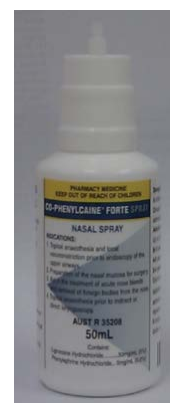5% lignocaine + 0.5% phenylephrine

- 1 spray is 100 µl
- 5% = 5 g/100ml = 50 mg/ml = 5 mg/100µl
- 5 mg lignocaine per spray

Recommendation is 4 squirts per nostril

Allow at least 5 mins for effect

Has an unpleasant taste

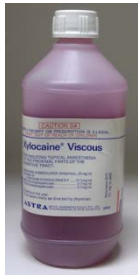

Lignocaine 2% jelly

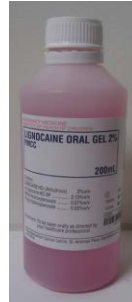Lignocaine jelly can be squirted directly into nostril or used with “serial dilatation” using nasopharyngeal airway



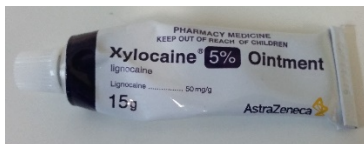
Lignocaine 2% viscous



Lignocaine 2% oral gel



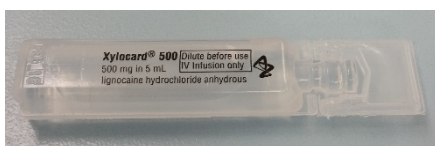
Lignocaine 5% ointment



Lignocaine 4% solution

Not available anymore, use 10% solution to dilute
(4ml of 10% solution diluted to total 10 ml with normal saline)

Lignocaine 10% solution (Xylocard)



Cocaine

Provides both topical anaesthesia & vasoconstriction

Preparations: 4-10% depending on institution

Maximum dose: 200 mg (US) or 1.5 mg/kg (UK)

Onset: 3-5 mins (anaesthesia)
5-10 mins (vasoconstriction)

Moffett's solution: 2 ml 5% cocaine + 1 ml 1:1000 adrenaline + 2 ml sodium bicarbonate

Mechanism of action

1. Acts on sodium channels Inhibiting their action → local anaesthesia
2. Blocks reuptake of dopamine in midbrain → euphoria/arousal then depression/craving
3. Blocks reuptake of noradrenaline in SNS → stimulates catecholamine release → hypertension, tachycardia, sweating

Pharmacokinetics

Nasal administration

- Twin peaks of absorption at 10 and 45 mins
- Fraction absorbed through nasal mucosa ~19%

Oral dosing

- Serum peak around 45 mins
- Bioavailability ~ 33%

Considerations

- There is a risk of coronary vasospasm and AMI regardless of age or health
- Some studies have shown equivalence of co-phenylcaine with cocaine
- Adrenaline use reduces plasma level of cocaine but this is unreliable

Local Anaesthetic Delivery

There are countless ways of delivering local anaesthetic. Listed here are the more common ones. It is a personal choice based on availability at your institution.

Broadly speaking they can be broken up into 4 methods:

- Atomisation
- Nebulisation
- Topical application
- Nerve blocks

Useful endpoints are loss of gag and voice change.

Atomisation and nebulisation methods are short acting. They'll provide around 10-15 mins of effective topicalisation once the endpoints are reached. It is extremely important to start the intubation quickly once the topicalisation is finished. This will require a high degree of organisation beforehand.

Atomiser

Reduces liquid medicines to fine particles in the form of a spray or aerosol. The smaller particles travel further down the airway and improve topicalisation

DeVilbiss atomiser

Can be very effective

Problems with CSSD (not available in St. Vincent's)



LMA MAD Devices

Oral MAD



Nasal MAD

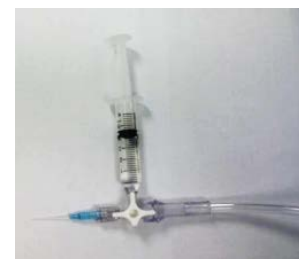

The soft plastic coating around the oral MAD can be pre-shaped to facilitate delivery into the nostrils, oropharynx and into the larynx. It needs a certain amount of force on the plunger of the syringe to generate atomisation.

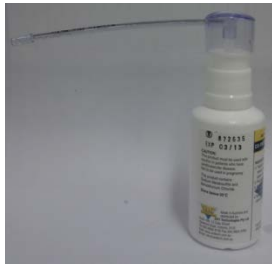"Home-made" atomiser

Can be quite effective

Oxygen tubing, 3-way tap, 5 ml syringe,
22G cannula (stylet removed)



Spray Nozzles



The one on the left is a better atomiser. The one on the right is more likely to squirt a jet of liquid rather than atomise which is unpleasant (and not as effective!)

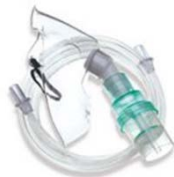Nebulisers

Reduces liquid medicines to extremely fine cloud-like particles. The disadvantage is that absorption of local anaesthetic may not be as good as atomisation.

Size of particles

- $>100\text{ }\mu\text{m}$ condense in mouth and pharynx
- $10\text{-}30\text{ }\mu\text{m}$ in mucosa of small bronchi
- $60\text{-}100\text{ }\mu\text{m}$ in bronchi and trachea
- $<3\text{ }\mu\text{m}$ in alveoli

Nebulising mask



Rebreathing circuit



There is loss of up to 50% of drug during spontaneous respiration with a nebuliser. Consider using a higher dose eg. $5\text{-}7\text{ mg/kg}$ taking into account of the loss of drug using the mask.

Advantages: Easy, simple, non-invasive, little discomfort, widely available

Disadvantages: Time consuming (can take 15-30 mins)
Possible inadequate laryngeal anaesthesia
Can set off the smoke detector alarm if using Xylocard

Topical application

Gargling

Useful for anaesthetising the oropharynx thus suppressing the gag reflex.

Use 4 ml of 2% lignocaine viscous (80 mg).

A “bubbled” solution tends to have better coverage.

Gargle for 20-30 secs and spit the remainder out.

This method does not anaesthetise the larynx or trachea.

Jelly in the nose

Squirted directly into nostril or with “serial dilatation” using a nasopharyngeal airway

It allows estimation of appropriate tube size although it is only an estimation as nasopharyngeal airways are softer and more pliable than an ETT.

Disadvantages: uncomfortable, serial dilatation = reaming, can obscure view, epistaxis

Cricothyroid puncture

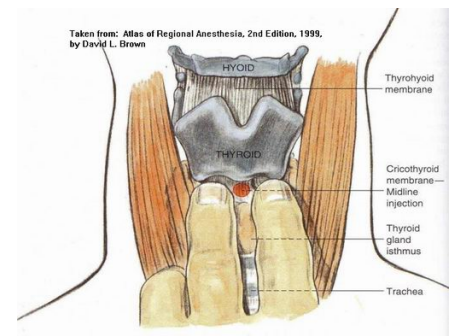
23G needle or 20G cannula with syringe of 2-4% lignocaine (2-3 ml)

- Clean skin, aspirate as you go through cricothyroid membrane, aspirating air as an end point
- Inject local anaesthetic on deep inspiration
- May induce violent coughing (must warn patient)
[prior nebulisation may minimise coughing]

Not suitable for unstable necks

Good for practising cricothyroid puncture for CICO situations

Some would advocate use of a 19G needle for quick injection



Spray as you go

Use an epidural catheter

- Cut tip off so it sprays forward, epidural catheters have side holes!
- Place down the working channel of fiberscope

Alternatively 5 ml syringe with 2 ml solution and 3 ml air directly into working channel

Caution: If you use suction it will suck the solution out of the syringe

3 separate areas to topicalise:

- Epiglottis, vocal cords, trachea (optional)
- 2 ml aliquots each of 2-4% lignocaine, wait 2 mins before moving to next area

Be patient! You can enter and exit multiple times.

Nerve blocks

Covered under anatomy section.

Lignocaine sample total

Oral

6 ml 4% lignocaine MAD device	= 240 mg
2% viscous gargle 4 ml	= 80 mg
6 ml 4% lignocaine "spray as you go"	= 240 mg

Total = 560 mg (8 mg/kg for a 70 kg person)

Nasal

Co-phenylcaine 5 sprays per nostril	= 50 mg
6 ml 4% lignocaine MAD device	= 240 mg
6 ml 4% lignocaine "spray as you go"	= 240 mg

Total = 530 mg (7.5 mg/kg for a 70kg person)

Sedation & IV Analgesia

Sedation

Adequate sedation can provide anxiolysis and prevent patient recall. However, sedation is entirely optional. Different consultants use it routinely whereas some may not use it at all. If you have adequately prepared the patient (mentally and optimally topicalised), sedation may not be necessary. If the reason you're not using sedation is because of respiratory compromise an awake intubation may not necessarily be the best course of action. If topicalisation is inadequate, do not persist with the intubation as the patient may never consent to another awake intubation.

- **Midazolam:**
 - Slow to titrate, moderate duration, reversible, familiar
- **Propofol:**
 - Fast titration, short duration, **suppresses laryngeal reflexes**
 - TCI better for ease of titration
 - Not reversible
- **Dexmedetomidine:**
 - Sedation and analgesia with minimal respiratory depression
 - Requires a loading dose
 - No antitussive effects, slow titration and not reversible
- **Ketamine:**
 - Sedation and analgesia with minimal respiratory depression
 - Secretions can be problematic
 - Verbal communication with the patient can be unreliable

Analgesia

Good analgesia can make the procedure much better tolerated and supplement topicalisation. Opioids have antitussive effects and are reversible but carry a risk of apnea at high doses.

- **Fentanyl:**
 - Slower to titrate, moderate duration, familiar
- **Remifentanyl:**
 - Rapid titration, short duration
 - Potential for intense analgesia (and respiratory depression)

Studied Regimens

Remifentanil vs fentanyl + midazolam

- Remifentanil group tolerated nasal tube passage and laryngeal tube advancement better but had more recall

Propofol OR Remifentanil TCI

- Both groups good intubating conditions and patient comfort but propofol group were more sedated

Propofol AND Remifentanil TCI

- Satisfactory conscious sedation, little recall

TCI Regimen

A target controlled infusion is your best chance of rapid and accurate titration.

Propofol TCI

- Marsh (plasma site targeting) start at 1 µg/ml, unlikely to need more than 1.5 µg/ml
- Schnider (effect site targeting) for elderly patients

Remifentanil TCI (Minto)

- Start at 2-3 ng/ml titrate up to 4 ng/ml if necessary (higher if recreational opioid use)

Needs to run for at least 5 minutes before intubation.

Aim for conscious (not unconscious) sedation ie. easily rousable whilst maintaining airway and respirations. In unconscious sedation, laryngospasm can result from touching the vocal cords. If this occurs spray the cords with 2% lignocaine and wait till they open.

Once you've railroaded the tube into the trachea, turn both up to 5.

Only inflate the cuff once the patient is asleep if you haven't done nebulisation or a transtracheal puncture.

Using a muscle relaxant is optional with this technique.

Module 5: Bronchoscopic Technique

Steps for an Awake Intubation

- Prepare patient (explanation/consent)
- Antisialagogue early
- Prepare equipment
- Topicalisation ± Vasoconstrictor (Nasal)
- Sedation/Analgesia
- Intubation

Aims for an Awake intubation

- “Quick”/Minimal delay
- Ideal visualisation conditions
- Optimal topicalisation
- Minimal patient discomfort
 - Especially patients likely to return (“I am NOT having the black snake again...!”)
- Sedation/Analgesia is optional but may give you a little safety net if your topicalisation isn’t perfect
- Ability to do solo (when you have the appropriate level of experience)

Awake Oral technique

- Effective topicalisation paramount
- Repeat if necessary. Keep in mind maximum dose of lignocaine
- Stay in the midline
- Maintain the oropharyngeal space (Ovasappian, pulling tongue forwards)
- Optimise position (head neutral)

Awake Nasal technique

- Pick an appropriate sized tube
- Pick the more patent nostril but topicalise the other nostril as well.
Vasoconstricting the more obstructed nostril can sometimes shrink the turbinates so much it becomes the more patent nostril
- Go under the inferior turbinate along the floor of the nose

Oxygenation

Don't forget about oxygenation and someone listening/looking at the O₂ saturation

Can deliver oxygen in a variety of ways:

- Through nasal prongs (if doing oral intubation)
- Through a nasal catheter (opposite nostril if nasal intubation). This can also be placed orally with some topicalisation. Catheter tip placed posterior to the tongue. Can be very useful as provides some apneic oxygenation.
- Through the suction port of the scope
 - In bloodied airways (due to inadvertent turbinectomies) or those with lots of secretions, 10 l/min O₂ through the suction port can significantly improve the view
- Through a paediatric tube in opposite nostril (you could connect CO₂ monitor here too)

Asleep technique

Train your assistant to:

- Tongue pull (less cervical movement):
 - Use a piece of green gauze, grab the tongue and pull
- Jaw thrust (more cervical movement):
 - Not recommended if there is an unstable cervical spine

Protect the scope

- Ovassapian (or other available oral aid)
 - Helps maintain midline position
- Bite block
 - May distort structures and move you off the midline
- Alternative
 - Insert tracheal tube 4-5 cm to protect the scope (less ideal patient can still bite down)

A well trained assistant can pull the tongue, hold the Ovassapian in place and also do jaw thrust all at once.

Plan B

It may not be possible to do a successful fiberoptic

Make sure you have a Plan B

No technique is failsafe

An awake fiberoptic intubation is not the only answer to a difficult airway

Glidescope-assisted Fibreoptic Intubation

Can be done with patient awake (with suitable topicalisation) or asleep.

Option 1

Operator 1 inserts Glidescope in the usual manner

Operator 2 (registrar/consultant) manipulates fibrescope into position

Operator 1 monitors the Glidescope display to see where the tip of the fibrescope is located

Option 2

Operator 1 inserts Glidescope in the usual manner with left hand

Operator 2 (may be a nurse) holds fibrescope handle and flexes fibrescope under Operator 1's instructions

Operator 1 holds distal end of fibrescope in right hand and uses the scope as a flexible stylet to intubate

Advantages

The Glidescope can open up the lumen of the pharynx and larynx.

The Glidescope is useful to see if endotracheal tube is getting caught on arytenoids and appropriate corrective action can be taken.

Useful if despite best attempts the fibrescope's image is not ideal due to unnavigatable anatomy or soiling of the airway.

Preoperative Nasendoscopy

Visualisation of the upper airway by nasendoscopy is a quick and potentially rewarding examination in patients who have known or suspected upper airway pathology. Nasendoscopy may have been performed months previously and should be repeated if there is a change in symptomatology or suspicion of a rapidly changing lesion. Information derived from this examination can direct airway management. It can be very well tolerated in experienced hands which have the required dexterity.

In a prospective study of 140 patients presenting for diagnostic or therapeutic airway procedures by Rosenblatt and colleagues, a preoperative endoscopic airway examination was performed following a standard airway examination and management plan. In 26% of patients, it had an influence on the original airway management plan.

Contraindications

Epiglottitis or obstructed upper airway with stridor (risk of inducing laryngospasm)

Coagulopathy (relative contraindication)

Method

Stage 1: Preparation

Explain procedure

Risks: Discomfort like having nose picked a bit too far back, makes eyes water

Position: Sit upright with head support

Topicalisation: Co-phenylcaine sprays to nostril

Stage 2: Passing the nasendoscope

Lubricate the scope

Stay in an airspace

When moving from nasopharynx to oropharynx, ask patient to breathe through the nose

Stage 3: Examination

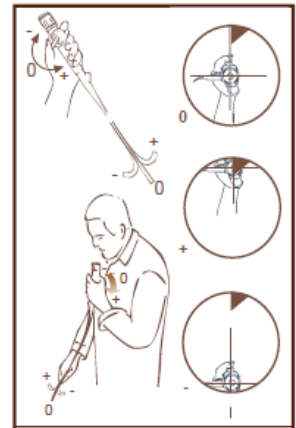
Manoeuvres to improve visibility

- Fricative sounds raise the soft palate ie. F and V sounds which bring the mouth into position to partially block the passage of air
- Protruding the tongue allows examination of tongue base
- Blowing the cheek out or saying "Eeeee" gives a clearer view of pyriform fossae
- Check vocal cord movements: "Eeeee" or counting numbers should adduct both cords: breathing in should abduct the cords equally

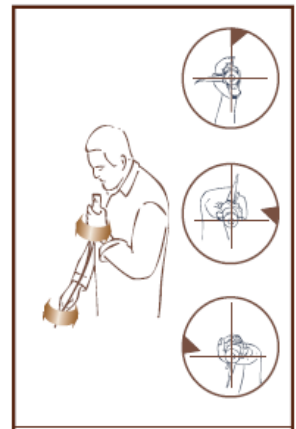
Basic Movements of the Scope

The scope can only be manipulated in 3 ways

1. Flexion/Extension of the tip:
 - Moving the angulation lever up moves the tip down and vice versa



2. Handle rotation:
 - Flexion/extension of the wrist (not body or shoulder)
 - For the movement in the handle to translate to the tip, you have to keep the insertion cord straight



3. Cord forwards/backwards

Oblique movements are a combination of all 3 ways.

All the movements are essentially in the thumb and wrist, you should not have to twist your body.

Endoscopic grip

Whether you hold the handle with your non-dominant or dominant hand is down to personal preference. Holding the handle with your non-dominant hand is akin to holding a laryngoscope, which allows the dominant hand for fine manipulations of the distal end of the scope.

Endoscopic manoeuvring

3 step rule

1. **Stop:** Stop and identify where you want to go
2. **Centre:** Place the target in the centre of the view
3. **Move:** Once centred, move towards the target

Start by making small movements and keep repeating the 3 step rule.

Tips 'n Tricks

General

Don't rush but equally don't take too long or the topicalisation can wear off

Your first go is your best go, slow and steady

If you maintain verbal contact with the patient it may help to allay their anxiety

Titrate sedation carefully to aim for conscious sedation

Equipment

Orientate and focus the camera if using a non-videoscope with a camera attachment

Make sure the light source is not on standby (non-disposable scopes)

Assemble the bullet-tip tube before loading onto the scope

Scope needs to be properly lubricated just before insertion

Technique

Bed at the lowest, step if needed - permits you to hold the scope straight

Keep the scope straight - prevents loop formation which limits your ability to rotate

Put a finger on the patient to help stabilise yourself

Watch the tip of the scope as you enter the nose or mouth

If it's not going one route, try a different route

Always keep the scope in an airspace - Don't blindly ram into mucosa unless you're really desperate (very low yield)

If your image fogs up, gently touching the mucosa may clear the tip (saliva is an excellent anti-fog)

When attempting to pass the tip of the scope over the arytenoids, try not to overflex the scope. The solution may be to (counter-intuitively) retroflex the tip slightly and "walk it over the hump" and you may feel a small "give" as you pass through

If the ETT is catching on a structure, first withdraw (disimpact), rotate and then reinsert to shift the axis of the ETT more favourably

Don't touch the carina with the scope (hard to topicalise well)

Ask your assistant to hold the scope whilst you railroad the tube. If you're holding the scope yourself you may inadvertently pull the scope (out of the trachea) whilst you're attempting to push the tube in.

PRACTICE, PRACTICE, PRACTICE...

Module 6: Benchtop Training

The essential components of successful endoscopy are **familiarity with equipment, patient management, anatomy recognition** and **dexterity**.

The first three components can be learned at a cognitive level.

Bronchoscopic dexterity is primarily a psychomotor skill requiring considerable hand-eye co-ordination. It requires cognitive awareness as well as directed “hands on” learning combined with ongoing practical application.

Every individual will require time to acquire and refine a psychomotor skill. Bench practice and subsequent skill transfer to patients has been successfully demonstrated and form part of a structured program for bronchoscopic skill training. A study by Chris Marsland showed that trainees typically need 2-4 hours of benchtop training to achieve proficiency in driving the bronchoscope.

Bronchoscopic skill training is recognised as the hardest to learn and the easiest to lose.

Dexterity must first be learned and then maintained to prevent decay. Non-anatomic bench models such as the Dexter develop the skill component of bronchoscopic dexterity. Virtual reality models such as the ORSIM are also useful for developing dexterity, as helping to recognise certain structures. The downside to the ORSIM is it cannot virtualise a large unsupported airspace such as the mouth to the larynx. Anatomic bench models such as the Broncho Boy develop the anatomic recognition component but only require a basic level of dexterity.

Dexter

Dexter is non-anatomical and modular. Unique mechanisms can therefore be invented to achieve specific learning objectives. The modular design provides a variable bronchoscopic landscape intended to stimulate interest, prevent model recognition, allow multiple levels of difficulty and anticipate future development.

Dexter is supported by a structured educational system in the form of a training manual. This comprises cognitive, psychomotor skill training and practice sessions. The cognitive component is a primer of endoscopy detailing the optical and mechanical characteristics of endoscopes. The skill training section comprises a series of modules and accompanying exercises with specific learning objectives. The practice session section provides examples of game plans for practice, competition, assessment and workshops.



Approach to Dexter

Dexter is situated in the Computer room. There is a decommissioned scope (Olympus LF-GP) you can use with a portable light source on Dexter. Please do not leave the light on and treat the scope with care. If you are unfamiliar with the setup or want to use a decommissioned Olympus LF-V instead with the fibreoptic tower, please ask Crispin.

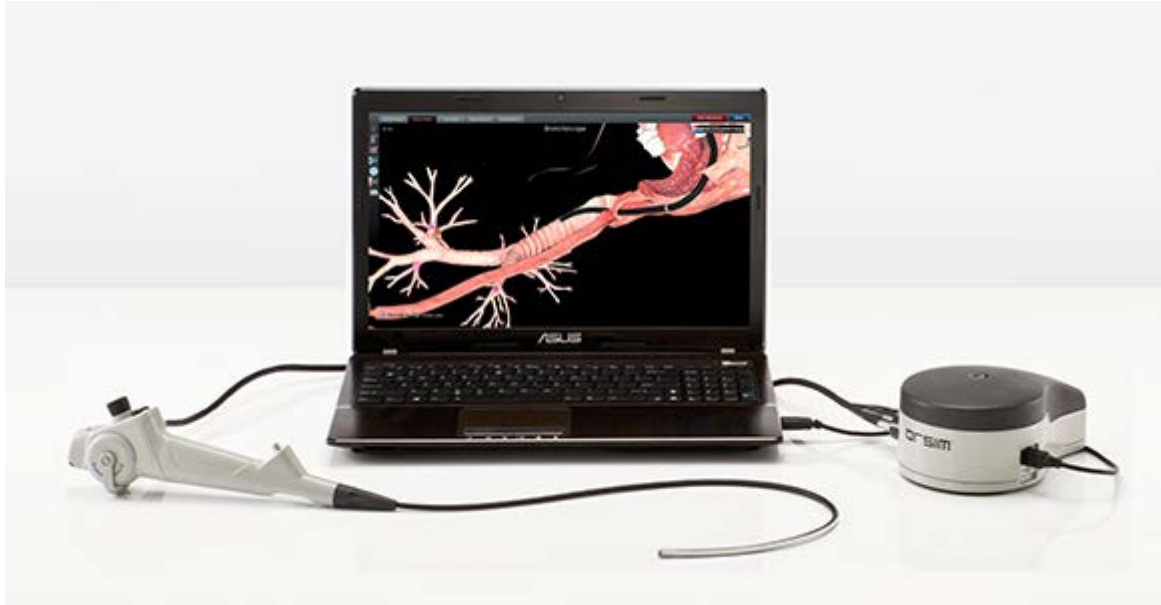Aim to be proficient driving the scope from above Dexter and also in front of Dexter (ie. Opposite movements).

You should aim to work through to Module 5 of the Dexter Training Modules. A summarised version of the modules is also available.

You should practice for 0.5-2 hours in divided sessions.

ORSIM

The ORSIM consists of three main parts. The replica video bronchoscope is inserted into the small desktop sensor. The sensor registers movement of the insertion tube and translates this to a 3-D virtual airway displayed through the software on the laptop screen. The user can progress through a range of upper and lower airway scenarios receiving instant feedback as well as scoring metrics, recording and playback.



Tutorial Layout

- Basic Skills
 - Oral Bronchoscopy, Nasal Bronchoscopy, Gopher Chase
- Upper Airway Anatomy
- Bronchial Anatomy
 - Identify Lung Segments, Naming Bronchial anatomy, Time Trial, Identify Lung Segments – Test
- Bronchial Navigation Tests
 - 5 sets
- Conduits and Airway Lesions
 - Laryngeal Lesion, Epiglottitis, Base of Tongue Lesion, Using an Intubating Airway, Using a Laryngeal Mask
- Difficult Airways
 - Vestibular Lesion, Retropharyngeal Abscess, Carcinoma of Tongue, Severe Epiglottitis, Macroglossia, Airway Trauma

Approach to Tutorials

Ask one of the bronchoscopy module supervisors to supervise your initial use of the ORSIM. The ORSIM is located in the Computer Room. Like any scope it can be damaged. Treat the scope with care and be gentle with it. Never force the scope as you will break it. If you break it it's potentially very costly to repair.

Initially work through the basic skills section, including the Gopher chase. You should try to get at least a 50% score on the Gopher chase before you proceed to the other modules. The Gopher chase is scored on speed and accuracy. After that you can work through the other sections. You can forego the bronchial sections until you do the Thoracics module.

The ORSIM doesn't exactly tell you how to have good technique for bronchoscopy but is good to train your dexterity. The general aims are to aim for good progression with minimal collisions.

You should practice for 0.5-2 hours in divided sessions.

Assessment

On completion of your bench-top practice, you'll be assessed on a customised Dexter layout using the rating scale below. Your overall aim should be to attain an expert level of dexterity.

Global Rating Scale of Fibreoptic Bronchoscope Manipulation (GRS)

Score	1	2	2.5	3	3.5	4	5
	Novice			PROFICIENT			Expert
View of Central Airway	Frequently loses view	Loses view more than once		Loses view of central airway no more than once		Maintains view	Maintains in centre of field of view
Mucosal Contact	Frequent collisions	Collides with airway structure		No collisions Infrequent glancing mucosal contact		Minimal mucosal contact	No mucosal contact
Progress	Hesitant, jerky inaccurate attempts to progress	General hesitancy Occasional progress		General progress, Occasional hesitancy		Smooth progress Occasional inaccuracy	Progresses smoothly and accurately between sequential landmarks
Orientation	Disorientated	Often disorientated		Image usually orientated		Mostly orientated	Fully orientated

Following a minimum assessment of being proficient, selected trainees can be rostered to ENT nasendoscopy/voice clinics to gain further experience.

Module 7: Intubating through a LMA

Intubating through a LMA with a fiberoptic has a very high success rate. Using a blind technique with a bougie through a LMA has a variable success rate as low as 30%.

It is important to know which LMA you can fit an ETT directly into and which ones you can't.

It is easy to focus only on intubation, however the focus should always remain on oxygenation. In a CICO situation you should leave the LMA in-situ and not attempt tube exchange.

Maximum ETT size fitting through a LMA

	Classic	i-gel	AuraGain	Supreme	Fastrach	Proseal	Reinforced
LMA Size 3	6	6	6.5	Not Suitable	7	5	4.5
LMA Size 4	6	7	7.5	Need Aintree	7	5	4.5
LMA Size 5	7	8	8.0	Need Aintree	8	6	5.5

In a stressful situation consider selecting another size down as the listed are maximum sizes. Also make sure you lubricate the ETT well.

Integrated Gastric Channel

Sizes in Fr

	Supreme	i-gel	AuraGain
Size 3	14	12	14
Size 4	14	12	14
Size 5	14	14	14

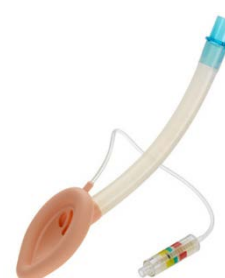LMA Classic

Relatively small internal diameter

Better suited for fiberoptic with Aintree catheter as exchange

unless you've a size #5 which can take a #7.0 ETT

Can ram the ETT pass the bars without cutting them



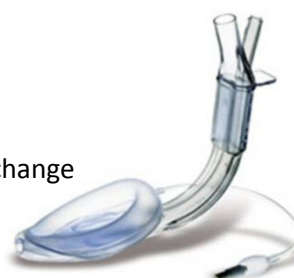LMA Supreme

The ventilation channel has the gastric channel going through the middle of it, which significantly limits passage of anything through it

Because of the gastric channel, as you exit into the larynx the scope will not be in the midline

It is not possible to stick an ETT through, you have to use an exchange method ie. with an Aintree catheter loaded onto a fiberoptic

It's a very tight fit with an Aintree catheter into a size #3



i-gel

Size #3 is recommended to have a #6 ETT


a #7 ETT can fit but is very snug

The advantages of using the i-gel are that it can be left in-situ

and there is no inflatable cuff

Some hospitals may not have the i-gel available

You'll probably tape the tube onto the end of the i-gel

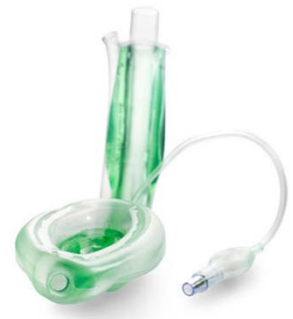

Ambu AuraGain

Similar in concept to an i-gel but it has an inflatable cuff

Can leave in-situ

Going to be replacing Supremes soon in this department



Other devices

Proseal: doesn't have the gastric port going through the middle

Size #3 fits #5 ETT, size #4 fits #5 ETT, size #5 fits #6 ETT

Reinforced LMA: not recommended for intubating through

It's unlikely you'll be using this LMA if you're having trouble ventilating

Airway Catheters

Below is a table of all the airway catheters we have in the department.


	Colour	Diameter (Fr)	Diameter (mm)	Length (cm)	Internal Diameter	Minimum ETT Size	Minimum DLT Size	Wire Length (cm)
Frova "Bougie"	Blue	14	4.7	70	3.0	6.0		-
Aintree Catheter	Light Blue	19	6.3	56	4.7	7.0		-
Cook AEC (Narrow)	Purple	11	3.7	100	2.3	4.0	35 Fr	-
Cook AEC (Wide)	Green	14	4.7	100	3.0	5.0	37 Fr	-
Cook SES	Purple/ Green	14	4.7	83		5.0		145

"Gum elastic bougie" is a historical term. Bougies are used for serial dilation of strictures. The current "bougies" that we have are neither gum or elastic. Tracheal tube introducer is a more accurate name.

AEC = Cook Airway exchange catheter

SES = Cook Staged Extubation Set

Aintree catheter



Designed to fit over the scope except for the distal 4 cm (flexible part)

Length 56 cm (Scope 60 cm)

Internal diameter 4.7 mm

External diameter 6.5 mm (Need \geq #7.0 ETT)

Does not fit over the aScope 3 (external diameter 5.0 mm)

Fits over the aScope 3 Slim (external diameter 3.8 mm)

Intubating with the Aintree catheter

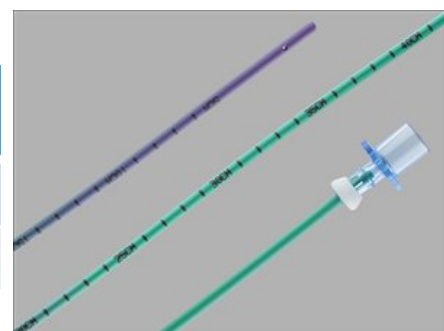
- Place LMA in oropharynx
- Load Aintree catheter on bronchoscope
- Manoeuvre bronchoscope into trachea
- Withdraw LMA over Aintree
- Remove LMA and bronchoscope
- Railroad ETT over Aintree (suggest having a videoscope ready to see if ETT is snagging on any structures)

Note: not suited for a CICO situation as you're removing a working airway device

Cook exchange catheter

We have two sizes in our department

	Catheter length cm	Catheter ID mm	Minimum ETT size
Size 11 Fr	100	2.3	≥ 4.0
Size 14 Fr	100	3.0	≥ 5.0



Long enough to railroad a double lumen tube

The smaller diameter one tends to bend easily

If you're having trouble railroading a tube, a videolaryngoscope can help you see which structure it's getting snagged on

Comes with two Rapi-Fit adaptors to facilitate ventilation through the catheter if required

LMA removal with Cook Exchange Catheter

Taking LMA out after ETT insertion

Safer to do with a Cook exchange catheter (CEC)

Use the size 11 Fr one as it is narrower

Sequence is as follows:

- Place LMA in patient
- ETT placed through LMA under bronchoscope guidance
- Check ventilation
- Withdraw bronchoscope
- Put in CEC, being mindful not to put it in too far as you may puncture the lung
- Remove ETT connector
- Pull LMA out over CEC and ETT
- As soon as the LMA is out far enough, secure the ETT with your finger in the oropharynx whilst you pull out the LMA

Problems with LMA removal using CEC

For i-gel/AuraGain sizes #4 and #5 there is enough space for the CEC, ETT and pilot balloon of ETT

However in a fully inflated balloon it might be an issue

For size #3 it is an extremely tight fit

You will probably have to deflate the balloon and remove the CEC before the LMA can slide out completely

Do not attempt this in a CICO situation in case you lose the airway completely

If in doubt, leave the LMA in

Fastrach

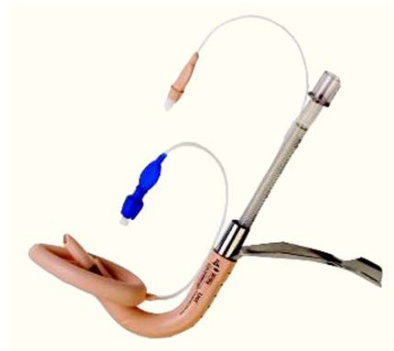
Disposable and non-disposable options.

We have both.

Very good success rate without fiberoptic aid, even better with fiberoptic aid.

Exchange can be fiddly.

Need familiarity.



Tube first intubation technique:

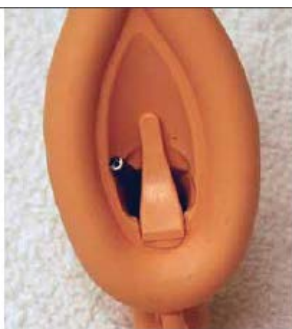

Figure 16. Standard-size fiber scope will often be deflected laterally due to the relative stiffness of the elevator bar, thus making passing and entrance into the glottic opening difficult.

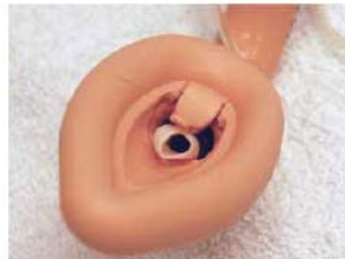

Figure 18. ETT emerging from LMA Fastrach as it lifts the "epiglottic elevator bar."

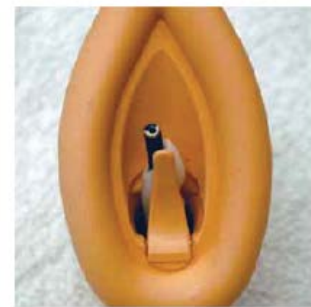

Figure 17. To overcome the stiffness of the elevator bar, first advance the ETT to elevate the "bar" (just past the black mark on the LMA-ETT, approximately 17-18 cm depth), then advance the fiber scope through the ETT toward the glottis.

What would I do if the plan was intubation through an LMA

Q: At St. Vincent's public?

A: Preferentially use an i-gel

Alternative: Fastrach

Q: At the Eye & Ear?

A: Preferentially use a Fastrach (is available in size #3, 4, 5 in OT & DSU)

No alternatives available

Module 8: Thoracics

This module is only intended to cover using a bronchoscope with a double lumen tube or bronchial blocker. This module is not a replacement for a proper thoracics tutorial.

Double Lumen Tube

Most commonly used thoracics tube. It has two high volume, low pressure cuffs, one tracheal (transparent), the other bronchial (blue).

All DLT's have two curves at 90° to each other

- Proximal curve for oropharyngeal curve

- Distal curve to facilitate bronchial placement

Available in right or left-sided varieties

Sizing

Most common sizes used are:

- Males 39 Fr and 41 Fr

- Females 37 Fr and 39 Fr

Using a 35 Fr DLT has implications for which bronchoscope you use.

In general use an Ambu aScope 3 Slim which is recommended for 37 Fr DLT and above. It is a tight fit in a 35 Fr DLT with plenty of lubrication.

The Olympus LF-DP will fit in a 35 Fr DLT easily but is easily damaged so only use it if you're going down a 35 Fr DLT.

Left-Sided DLT

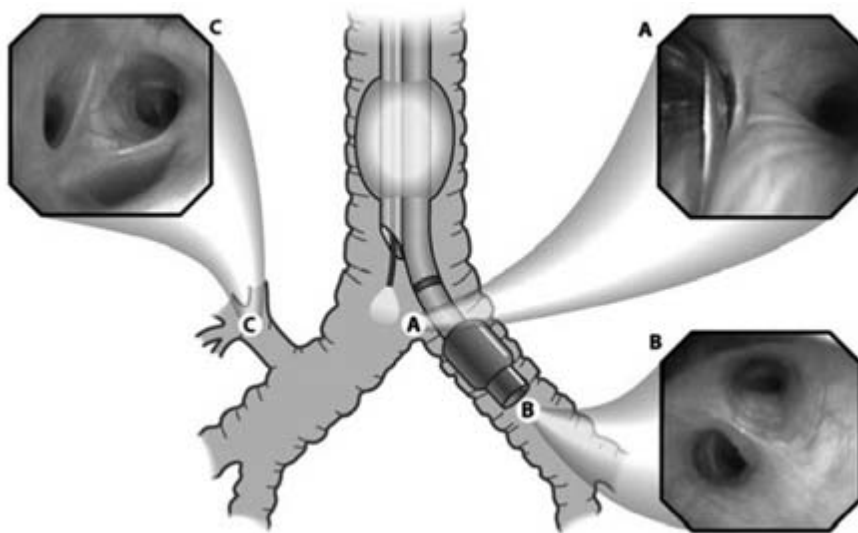
In a study by Klein et al, involving 200 patients who were intubated by the blind technique followed by confirmation with a bronchoscope, it was found that more than 1/3 of DLTs required repositioning.

If it's not deep enough the bronchial cuff will herniate into the carina.

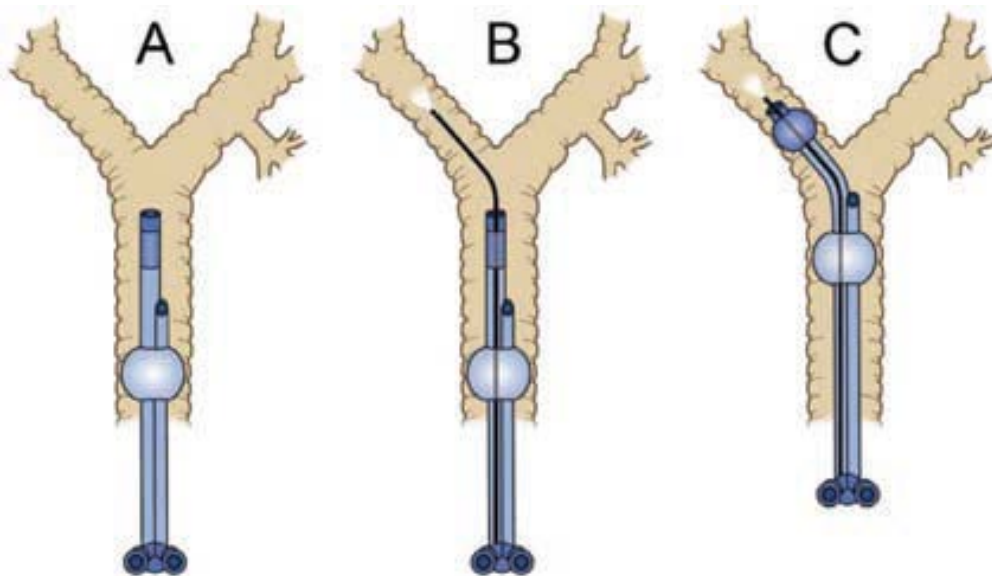
If it's too deep, it can cause obstruction of some left sided lung lobes.

Through the tracheal view, the blue endobronchial cuff ideally should be seen approximately 5 mm below the tracheal carina into the left bronchus. It is crucial to identify the take off of the right upper lobe bronchus through the tracheal view. Going inside the right upper lobe should reveal three orifices.

Through the endobronchial view, check for patency and determination of margin of safety. The orifices of both the left upper and left lower lobes must be identified to avoid distal impaction in the left lower lobe.



Using the bronchoscope as a guide into the left main bronchus:



Right-sided DLT

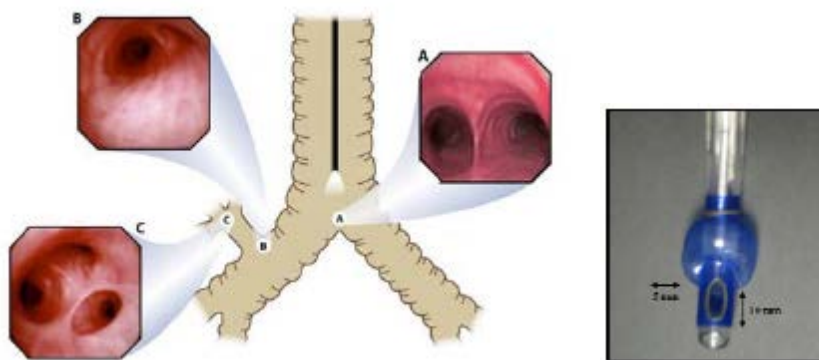
The right main bronchus is shorter than the left bronchus and the right upper lobe originates at a distance of 1.5 to 2 cm from the carina. The main problem with right-sided DLTs is obstruction of the right upper lobe.

Right-sided DLTs incorporate a modified cuff on the endobronchial side that allows ventilation for the right upper lobe.

The preferred technique for placement of a right-sided DLT is with the use of a bronchoscope.

From the endobronchial view, the proper position of the right-sided DLT is one that provides a good alignment between the opening slot of the endobronchial lumen in relationship to the take off of the right upper lobe bronchus and distally a free view of the bronchus intermedius and the right lower lobe bronchus.

From the tracheal view, the optimal position provides a view of the edge of the blue cuff just below the carina within the right mainstem bronchus.



Bronchial Blocker

Bronchial blockers are inflatable devices that are placed alongside or through a single lumen tracheal tube to selectively occlude a bronchial or lobar orifice.

It is indicated where DLT insertion is not possible or advisable

Eg. Difficult airway, lesions in the trachea, isolation through tracheostomy, selective lobar isolation

Limitations include slow collapse of the desired lung, inability to suction and provide CPAP and easy dislodgement.

Blocker Size Compatibility

It is crucial that you pick an ETT of adequate size to be able to fit the bronchoscope and the bronchial blocker into the ETT. Below is a table showing which bronchial blockers can fit down which size ETT using which bronchoscope. You should test the system prior to commencing.

If you're using a bronchial blocker you must seek out one of the senior thoracics anaesthetists eg. Des or Brian to get further advice on its use as it is not only a matter of fit.

We have two types in our department: Fuji and Arndt.

ETT Size ID	FOB		Cook 9Fr	Cook 7Fr	Uniblocker 9Fr
8.5	LF-V	4.1 mm	Possible	Easy	Easy
	aScope 3 Slim	3.8 mm	Easy	Easy	Easy
	LF-DP	3.1 mm	Easy	Easy	Easy
8.0	LF-V	4.1 mm	Possible	Easy	Easy
	aScope 3 Slim	3.8 mm	Easy	Easy	Easy
	LF-DP	3.1 mm	Easy	Easy	Easy
7.5	LF-V	4.1 mm	Possible NR	Easy	Easy
	aScope 3 Slim	3.8 mm	Easy	Easy	Easy
	LF-DP	3.1 mm	Possible	Easy	Easy
7.0	LF-V	4.1 mm		Possible	Possible NR
	aScope 3 Slim	3.8 mm	Impossible	Easy	Easy
	LF-DP	3.1 mm	Possible NR	Easy	Easy
6.5	LF-V	4.1 mm		Possible NR	
	aScope 3 Slim	3.8 mm		Possible NR	Impossible
	LF-DP	3.1 mm		Easy	Easy
6.0	LF-V	4.1 mm			
	aScope 3 Slim	3.8 mm			
	LF-DP	3.1 mm		Possible	Impossible

Possible Possible with generous lubrication (silicone spray) and careful insertion technique

Possible NR Technically feasible but Not Recommended

The Olympus LF-V and LF-GP are the same diameter (4.1 mm).

Most common setup:

- aScope 3 Slim using the Fuji Uniblocker with a minimum #7.5 ETT
this is acceptable with a #7.0 ETT but can be a tight fit.
- Only use the Olympus LF-DP if you've put down a #6.5 ETT.

The tighter the fit, the less ventilation is possible.

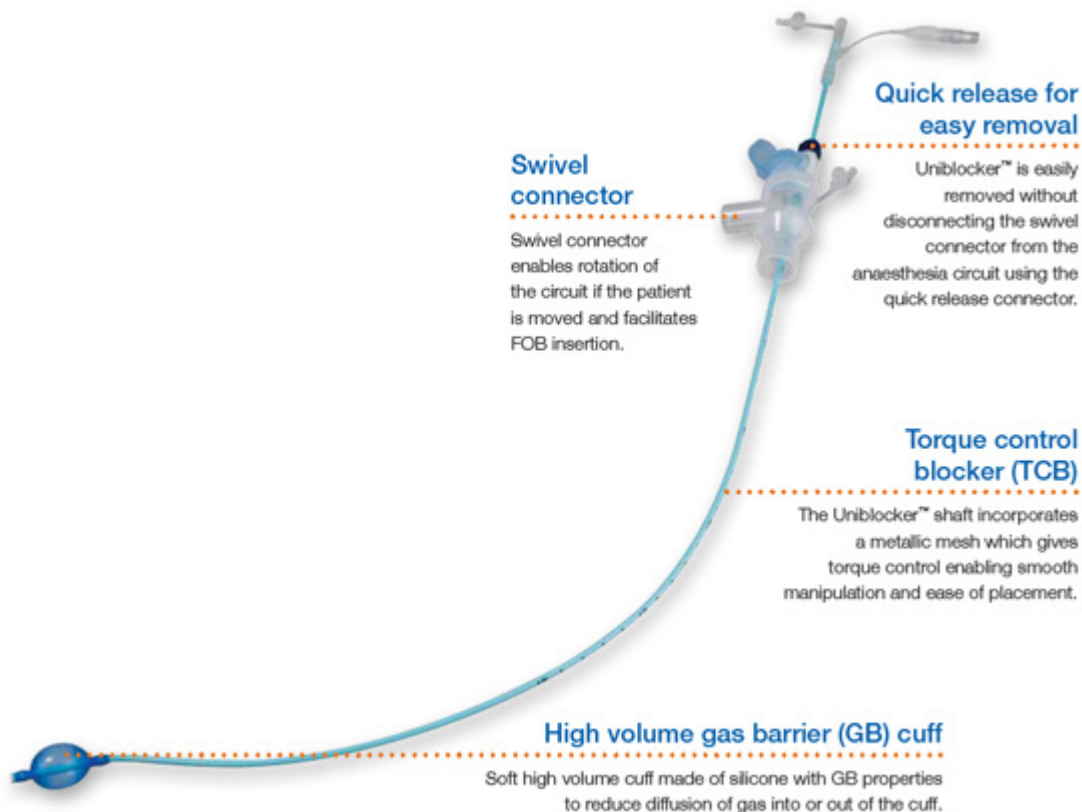
Fuji Uniblocker

Available in a 9 Fr size. The shaft is made from wire mesh coated with polyurethane, ensuring that any manipulation is translated to the tip of the blocker. It has a fixed distal curve which is useful for guiding it down to the intended bronchus.

Lubricate the bronchoscope and Uniblocker well. Attach the connector and put the bronchoscope down the blue port. Place the bronchoscope's field of view on the desired bronchus. Next push the Uniblocker down. The torque control shaft allows guidance into the desired target bronchus.

For blocking the right mainstem bronchus, the optimal position is the one that provides a view of the outer surface of the fully inflated balloon (4-8 ml of air) with the bronchoscope at least 5 mm below the carina.

The optimal position in the left mainstem bronchus is achieved when the blocker balloon's outer surface is seen with the bronchoscope at least 5-10 mm below the carina.



Arndt

Available as 7 Fr or 9 Fr, wire-guided, yellow catheter, 65 and 78 cm lengths, with cm markings.

It consists of a blocking catheter and an airway adaptor.

The blocking catheter has a blue coloured high-volume, low-pressure balloon, which is elliptical or spherical in shape

A flexible nylon wire passes through the proximal end of the catheter and extends to the distal end then exits as a small loop.

The airway adaptor has 4 ports:

1. 15 mm port that attaches to the ETT
2. Ventilation port that connects to the breathing circuit
3. Port for a flexible fibreoptic scope
4. Port angled approximately 30° for the blocker

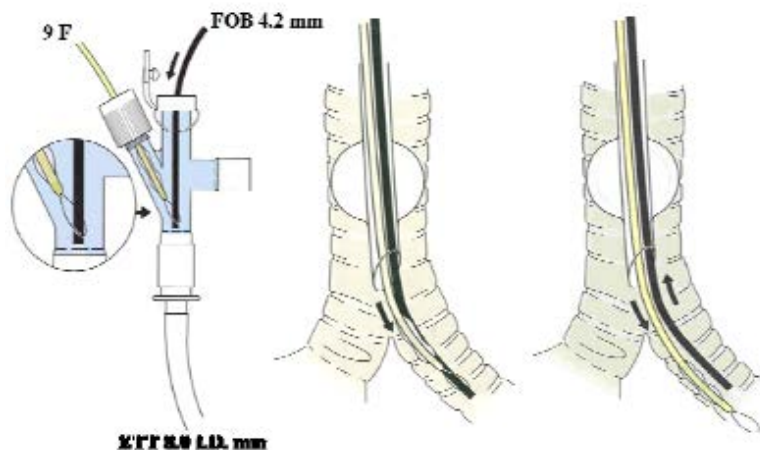
Technique

Lubricate the bronchoscope and the bronchial blocker well. Fibreoptic scope and the blocker are placed through their specific ports.

Left mainstem bronchus

Thread the bronchoscope through the wire loop inside the special connector and then tighten the wire loop as a snare just proximal to the flexible portion of the bronchoscope (~ 4 cm from the distal end). The entire unit is placed on the ETT and the circuit connected to the ventilation port, allowing continuous ventilation during placement.

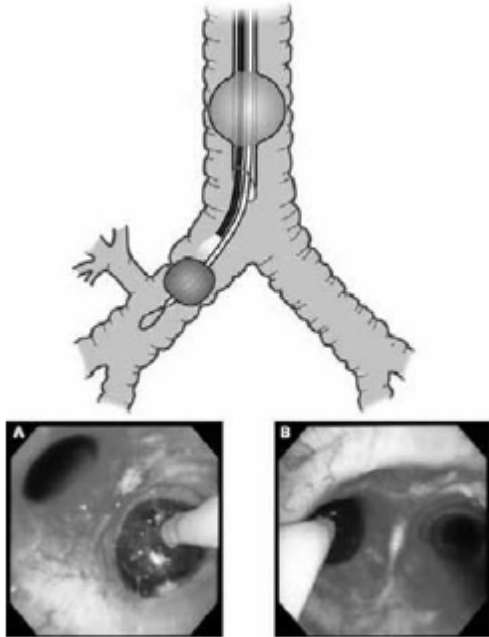
The fibreoptic scope is driven into the left mainstem bronchus. The snared blocker should drag along with the scope. The loop is then loosened and the blocker is gently passed down over the scope until resistance is encountered. The scope is withdrawn until the carina and the blocker are in view.



Right mainstem bronchus

The Arndt blocker can be advanced independently of the wire loop by observing its entrance into the right mainstem bronchus under bronchoscope visualisation. Alternatively loop it around the bronchoscope as you would going into the left main bronchus.

Before turning the patient, the cuff of the blocker should be deflated, then advanced 1 cm deeper to avoid proximal dislodgement. Placement is confirmed after positioning.



Bronchial Anatomy

It's useful to brush up on the anatomy of the lung. Here's a link to a video:

[Segmental Anatomy and Bronchoscopy on Vimeo](#)

Practical Points

Knowing the anatomy will allow you to work out where you are in the tracheobronchial tree which is very useful particularly when your tube is too far in.

Trachealis muscle runs posteriorly which will help you work out left from right.

The right upper lobe comes off early and has 3 segmental bronchi.

The left mainstem bronchus is about 4-5 cm long and splits into upper and lower lobes.

The left upper lobe splits early into an upper division and a lingular division.

The left lower lobe has 5 segmental bronchi with the first one coming off early.

Bronchial Simulator

Please use the simulator from the University of Toronto to see a virtual bronchoscopy simulation with real life images:

[VIRTUAL Bronchoscopy Simulation - PIE, Education, lungs, bronchus](#)

Further Reading

Appadurai IR et al., Nasendoscopy: a useful addition to the anaesthetist's armamentarium, *Anaesthesia* 2000, 55: 590-619

Graham J, Evolution of airway training at a large metropolitan teaching hospital, *Australasian Anaesthesia* 2013

Marsland C et al., Proficient manipulation of fiberoptic bronchoscope to carina by novices on first clinical attempt after specialized bench practice, *BJA* 104 (3) 2010 375-81

Naik VN, Fiberoptic orotracheal intubation on anesthetized patients, *Anaesthesiology* 2001; 95:345-8

Williams KA et al., Combined nebulization and spray-as-you-go topical anaesthesia of the airway *BJA* 2005; 95(4): 549-53

Johnston KD et al., Conscious sedation for awake fiberoptic intubation: a review of the literature, *CJA* 2013; 60:584-99

Mason RA, Editorial: Learning fiberoptic intubation: fundamental problems, *Anaesthesia* 1992; 47: 729-31

Sudheer P, Anaesthesia for awake intubation, *BJA CEPD Reviews* 2003; 3(4) 120-3

Vaidyanath C et al., Correspondence: Fiberoptic airway endoscopy training: Comparison of three different trainer models, *EJA* 2014; 31:1-2

Gil KSL, Fiber-optic intubation: Tips from the ASA Workshop, *Anesthesiology News* 2009

Techanivate A et al., Estimation of the proper length of nasotracheal intubation by Chula formula, *J Med Assoc Thai* 2008; 91(2): 173-9

Law JA, The incidence, success rate, and complications of awake tracheal intubation in 1554 patients over 12 years: an historical cohort study, *CJA* 2015; 62:736-44

Benumof JL, Editorial: Awake intubations are alive and well, *CJA* 2015; 62:723-6

Day RO, The death of a healthy volunteer in a human project: implications for Australian clinical research, *MJA* 1998; 168: 449-51

National airway training course for anaesthetic trainees Course

Benumof and Hagberg's Airway Management 3rd ed

Quick Reference

Bronchoscopes

Scope	Type	Outer diameter	Min. size ETT	Min. size DLT	Working channel	Length	Tip mvmt	Field of view
Ambu	aScope 3	5.0 mm	6.0 mm	41 Fr	2.2 mm	600 mm	150° up 130° down	85°
	aScope 3 Slim	3.8 mm	5.0 mm	37 Fr	1.2 mm	600 mm	130°	85°
Olympus	LF-V	4.1 mm	5.0 mm	37 Fr	1.2 mm	600 mm	120°	120°
	LF-DP	3.1 mm	4.0 mm	32 Fr	1.2 mm	600 mm	120°	90°
	LF-GP	4.1 mm	5.0 mm	37 Fr	1.5 mm	600 mm	120°	90°
	BF type PE2	4.9 mm	6.0 mm	41 Fr	2.2 mm	600 mm	180° up 130° down	120°

For an Awake/Asleep Intubation or Intubating through an LMA:

Use the following non-disposable scopes: **Olympus LF-V, LF-GP or BF type PE2**

If a non-disposable scope is not available use an aScope 3 (less gap) if available
otherwise use an aScope 3 Slim

The LF-DP is too slim (increased gap between scope and tube) and is easily damaged

For Thoracics:

Use this disposable scope: **Ambu aScope 3 Slim (Grey)**

With good lubrication it should fit into a DLT 35 Fr or if using a bronchial blocker

If not available use an Olympus LF-V

An alternative for a DLT 35 Fr is an Olympus LF-DP

Please refer to Bronchial Blocker Compatibility for scope compatibility with bronchial blockers

For Nasendoscopy:

Use an Olympus LF-DP (non-disposable) or an aScope 3 Slim (disposable)

LMA Internal Compatibility with ETTs

	Classic	i-gel	AuraGain	Supreme	Fastrach	Proseal	Reinforced
LMA Size 3	6	6	6.5	Not Suitable	7	5	4.5
LMA Size 4	6	7	7.5	Need Aintree	7	5	4.5
LMA Size 5	7	8	8.0	Need Aintree	8	6	5.5

i-gel #3 can fit up to a 7.0 ETT but not recommended by manufacturer

Supreme #3 has an extremely tight fit with an Aintree catheter and is not recommended

Aintree catheters are very stiff and do not negotiate corners well

Airway Catheters

	Colour	Diameter (Fr)	Diameter (mm)	Length (cm)	Internal Diameter	Minimum ETT Size	Minimum DLT Size	Wire Length (cm)
Frova "Bougie"	Blue	14	4.7	70	3.0	6.0		-
Aintree Catheter	Light Blue	19	6.3	56	4.7	7.0		-
Cook AEC (Narrow)	Purple	11	3.7	100	2.3	4.0	35 Fr	-
Cook AEC (Wide)	Purple	14	4.7	100	3.0	5.0	37 Fr	-
Cook SES	Purple	14	4.7	83		5.0		145

AEC = Cook Airway Exchange Catheter

SES = Staged Extubation Set

All the Cook catheters (AEC & SES) are purple with a green tip. Check the label which diameter catheter you want to use before opening.

Bronchial Blocker Compatibility

ETT Size ID			FOB	Cook 9Fr	Cook 7Fr	Uniblocker 9Fr
8.5	LF-V	4.1 mm		Possible	Easy	Easy
	aScope 3 Slim	3.8 mm		Easy	Easy	Easy
	LF-DP	3.1 mm		Easy	Easy	Easy
8.0	LF-V	4.1 mm		Possible	Easy	Easy
	aScope 3 Slim	3.8 mm		Easy	Easy	Easy
	LF-DP	3.1 mm		Easy	Easy	Easy
7.5	LF-V	4.1 mm		Possible NR	Easy	Easy
	aScope 3 Slim	3.8 mm		Easy	Easy	Easy
	LF-DP	3.1 mm		Possible	Easy	Easy
7.0	LF-V	4.1 mm			Possible	Possible NR
	aScope 3 Slim	3.8 mm		Impossible	Easy	Easy
	LF-DP	3.1 mm		Possible NR	Easy	Easy
6.5	LF-V	4.1 mm			Possible NR	
	aScope 3 Slim	3.8 mm			Possible NR	Impossible
	LF-DP	3.1 mm			Easy	Easy
6.0	LF-V	4.1 mm				
	aScope 3 Slim	3.8 mm				
	LF-DP	3.1 mm			Possible	Impossible

Possible	Possible with generous lubrication (silicone spray) and careful insertion technique
Possible NR	Technically feasible but Not Recommended

Bronchial blockers: Cook Arndt and Fuji Uniblocker

Recommendations:

- Discuss first with a senior thoracic anaesthetists eg. Des, Brian
- The tighter the fit, the less the ventilation when the scope is in the tube, so aim for a bigger tube than what just “fits”
- Fuji is somewhat less fiddly to use